



Articles & White Papers

Journal Index Book



VYDENCE is a worldwide leader of laser platforms with offices in Miami and São Paulo. The company has a strong, growth-driven distribution network in Canada, Latin America, EU and Middle-East.

VYDENCE is the market leader for tailor-made laser platforms that create and provide solutions for the natural beauty standards that go beyond results usually delivered by traditional technologies and procedures

Laser platforms are unique to VYDENCE, with exclusively featured handpieces such as handPICO® and ProDeep®, and up to 4 different technology platforms that combine multiple lasers and improves ROI for any business.

etherear



ethereamx[®]



Building an Aesthetic Practice Around a Multi-Platform Laser



Stephen Eubanks, M.D., FAAD
Advanced Dermatology and Cosmetic Surgery
Orlando, Florida

INTRODUCTION:

A new or existing practice that wants to expand into aesthetics must look at many things. The safety of treatments is primary; if treatments are not safe, nothing else matters. The next criteria are that all of the aesthetic treatments must be effective. The last criteria is that treatments must be economically sound. This latter item is seldom considered but is crucial to the success of a practice.

With the above three criteria established, one must look at what encompasses an aesthetic business. There are many treatments that are possible but the three main categories I feel are necessary include toxins, fillers and energy-based devices. I will only discuss energy-based devices in this paper.

The categories of energy-based treatments an aesthetic practice must provide include treatment of unwanted vascular conditions, treatment of unwanted brown pigmented conditions, fine to moderate wrinkles, scarring-especially acne scarring, stretch marks, unwanted hair, too little hair and tattoos.

WHAT ENERGY-BASED DEVICES ARE NEEDED IN AN AESTHETIC PRACTICE:

To treat unwanted red or vascular conditions, a pulsed dye laser (PDL), a long-pulsed Nd:YAG laser or an intense pulsed light (IPL) device should be considered. There are many options on the market for stand-alone lasers or IPL devices to accomplish the treatment of unwanted red conditions.

To treat unwanted brown or pigmented conditions, there is one pulsed dye laser, an alexandrite laser, a short-pulsed Q-switched laser, an ultrashort pico-second laser or an IPL device. As stated above, there are many stand-alone lasers or IPLs to treat unwanted brown.

Wrinkles have even more options with which to treat. Ablative fractional CO₂ lasers, ablative fractional Er:YAG lasers, picosecond lasers, several non-ablative fractional lasers, radiofrequency (RF) devices and ultrasound devices. Hair removal requires either Nd:YAG laser, alexandrite laser, diode laser or IPL. Tattoo removal requires a short-pulsed Q-switched or picosecond laser.

The options include the purchase of two, three or four separate stand-alone, expensive devices or consider combination platforms that may treat several conditions in one. There are some multi-platform devices that combine two lasers such as alexandrite and Nd:YAG lasers. There are some platforms that combine ablative fractional laser with RF devices. There are devices that combine IPL and RF or IPL with laser. There is only one platform, Etherea^{MX} (or Zye) from Vydenze Medical, that combines ablative fractional laser, fully ablative laser, non-ablative fractional laser, IPL, hair removal, Infrared skin tightening, Q-switched and picosecond lasers.

WHAT IS THE ETHEREA^{MX} MULTI-PLATFORM DEVICE?

This is a platform that has six main, separate, easily attached, plug-and-play applicators:

The handpico[®] applicator is the world's first fractional picosecond handpiece. This supports 532 nm and 1064 nm wavelengths with 3 mm and 5 mm full field laser delivery tips that can deliver either nanosecond or picosecond energy. There is also a 6x6 mm MLA (micro lens array) 1064 nm fractional picosecond delivery system. The handpico[®] applicator may treat wrinkles, tattoos, melasma, acne scars and unwanted skin pigmentation.

The ipl-sq[®] is a full featured IPL device with easily changed cut off filters at 400 nm, 515 nm, 540 nm, 580 nm, 640 nm and 695 nm. This high-power IPL can deliver pulses at 3 Hz through a large 12x40 mm rectangular lens, plus unique VascuTips with a 12x12 mm square lens or a 8 mm round lens for more accurate treatments in smaller, targeted areas. These lens options and multiple filters allow treatment of pigmented lesions, vascular lesions, active acne, skin rejuvenation and hair removal.

The most unique applicator is the ProDeep[®], a 1,340 nm Nd:YAP laser that can deliver a regular 6 mm solid pulse or fractional delivery with an 8 mm, 100 mtz/cm² and a 10 mm, 400 mtz/cm² spots. Standard uses include wrinkle reduction, scar treatment, stretch mark improvement, melasma and acne scar treatment. There have been off label articles written on treating

active acne, improving hair growth and treating hidradenitis suppurativa.

The ACROMA^{QS}[®] is a handheld, dual wavelength (1064nm/532nm) laser applicator. The 1064 wavelength has a solid 3 mm, 5 mm, and 7 mm spot. There is also a 9 mm, 100 mtz/cm² fractional spot available. This applicator has been used to remove tattoos, epidermal and dermal pigmented lesions and for "LASER toning".

The longpulse[®] is an Nd:YAG 1,064nm laser applicator with pulses ranging from 0.3 msec to 60 msec, making this both a long-pulse laser and a short-pulse laser. Available spot sizes are 2, 3, 5 and 9 mm. This combination of pulse duration and spot size allows for the treatment of leg veins, larger facial telangiectasias, hair removal and skin toning.

The DUALMODE[®] is an Er:YAG, 2,940 nm fractional and non-fractional laser. This is one of the most versatile applicators on the Etherea^{MX} platform. There are two collimated spots, a 2.5 mm and a 6 mm. There are also two fractional tips, an 8 mm, 100 mtz/cm² and an 8 mm, 400 mtz/cm². The beauty of this applicator is the ability to either treat as a single fractional ablative Er:YAG treatment or do a combination, within a single pulse, of the ablation found in typical Er:YAG with a longer pulsed, more coagulative pulse of energy. This is the dual mode from which this applicator gets its name.

All of the applicators may seem overwhelming, but each practice can start with the applicators they want initially and add as needed.

WHAT ARE SOME OF MY FAVORITE USES WITH THE ETHEREA^{MX}

I am currently using ProDeep[®] to replace some of my slower RF devices when treating acne scars. The discomfort is lessened and the speed of treatment is far better. The handpico[®] is so useful in treating mild textural changes of the skin and mild pigmentary abnormalities on the face. I am layering ProDeep[®] and handpico[®], first treating acne scars with 1,340 nm the fractional pico over the top. The ease to change from the ipl-sq[®] to the DualMode allows for layering of these two treatments also.

WHY DOES IT MAKE SENSE ECONOMICALLY TO US ETHEREA^{MX}?

Buying 3-5 stand-alone lasers or IPLs at \$80,000 to \$150,000 each is usually never financially a good option when either starting an aesthetic practice or converting from your current business to more aesthetics. The ability to bring energy into aesthetics with a reasonable start-up cost was never more important than in our current economic times. There are other attractive features that make it attractive as a provider: No consumable costs, no calibration time, two-year warranty for peace of mind, and rapid service support in a time when practices simply cannot afford to have any downtime.

SUMMARY

The three most important factors in an aesthetic practice -- safety, efficacy and economics -- all are satisfied with this multi-functional platform, the Etherea^{MX}.

Unique Nd:YAP 1340 nm Handpiece Offers Effective Acne and Acne Scar Tx

By John Jesitus, Contributing Editor

By providing deeper treatments safely, the unique and innovative Nd:YAP 1340 nm ProDeep handpiece for the ETHEREA-MX laser from VYDENCE Medical (São Carlos, Brazil) is an effective and FDA cleared option for non-ablative skin resurfacing.

According to Maurice Adatto, MD, the medical director at SKINPULSE Dermatology & Laser Center in Geneva, Switzerland, the ProDeep handpiece is unique due to its 1340 nm non-ablative neodymium:yttrium-aluminum perovskite (Nd:YAP) laser, which can penetrate up to nine times more deeply than other non-ablative lasers due to both its higher optical conversion efficiency than 1320 nm Nd:YAG and its water absorption curve specificity.

“The target of this infrared wavelength is water,” said Dr. Adatto. “If we look at the water absorption curve, 1340 nm penetrates deeper than the traditional 1540 – 1550 nm, offering potentially better efficacy.”

Also unique, is ProDeep’s ability to work in either bulk-heating mode, with a 6 mm collimated handpiece, or in fractional mode, with lenses offering either 100 or 400 microthermal zones (MTZ), he added. This range of versatility inspired Dr. Adatto’s research on using ProDeep for active acne and acne scarring. “For improving acne scars, heating the dermis produces new collagen. For reducing active inflammatory acne, the mechanism should directly target sebaceous glands, which are responsible for acne.”

ProDeep heats and shrinks these glands, thereby reducing their activity. In a study of nine patients with nodular-cystic acne resistant to isotretinoin, ProDeep treatment reduced average per-patient lesion counts from 16 to six – a 65% reduction.¹

“No topical anesthesia is needed and a good cleansing of the skin is mandatory prior to the session,” Dr. Adatto stated. “Our favorite settings for the face are two passes of 100 MTZ, 80 – 90 mJ and 3 ms pulses, always with cold air that is attached to the handpiece.” Patients typically require two to six sessions (the latter for very severe cases) spaced three to four weeks apart.

ProDeep can apply up to 220 mJ per MTZ in fractionated beams, generating greater heat in subdermal tissue, which results in deeper collagen remodeling in targeted tissues as well as quicker recovery times.

“Because the wavelength reaches deeper, patients have less visible erythema,” Dr. Adatto reported. Patients usually have slight redness for 24 hours post treatment, and some may have mild edema for 12 hours, he elaborated. Patients can usually return to normal activities the day after treatment.

A new 8 mm square spot shape available with the 100 MTZ lens ensures greater operator visibility, treatment coverage and accuracy. The square shape offers a 25% larger treatment area than round spots of the same size, which translates into faster treatments. Furthermore, the square spot enables the device to operate with a 30% smaller fractionated microbeam.

In practice, optical improvements increase the irradiance and depth of action as a function of the smaller total area while increasing safety and homogeneity of coverage area. The treatment is well-tolerated by most patients.

Dr. Adatto added that ProDeep is very easy to handle, with no consumables or preheating required. “You can start treatment in less than two minutes,” he stated.

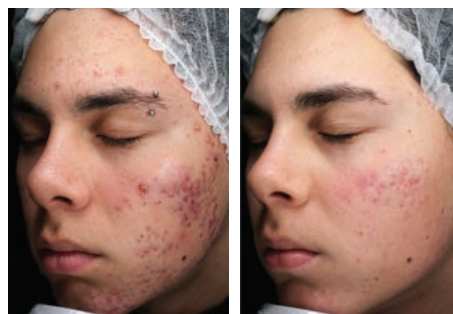ProDeep is part of the ETHEREA-MX platform, which incorporates seven technologies, five laser wavelengths and more than 70 FDA-cleared treatment indications. The device is also effective for reducing mild-to-moderate wrinkles and stretch marks, according to VYDENCE.

Reference:

1. Antonio CR, Antonio JR, de Oliveira G, Tridico LA, Borim MP. Use of non-ablative fractional 1,340 nm Nd:YAP laser in the treatment of nodulocystic acne resistant to isotretinoin. *Surg Cosmet Dermatol*. 2013;5:310-314.



Maurice Adatto, MD
Medical Director
SKINPULSE Dermatology
& Laser Center
Geneva, Switzerland



Before and after five sessions
with the ProDeep handpiece

Photos courtesy of Valeria
Campos, MD

Unique Nd:YAP 1340 nm Handpiece Enables Greater Versatility and Improved Outcomes

By Cindy Papp, Contributing Editor



Valeria Campos, MD
Clinica Valeria Campos
Jundiai, Sao Paulo, Brazil

Today's advanced technologies are creating a perfect opportunity for cosmetic surgeons to increase their repertoire of laser treatments to rejuvenate and improve their patients' skin. The ETHEREA-MX by Vydence is a laser-based platform that offers multiple applications in just one system and remains one of the most successful and versatile systems available today.

As the latest generation of fractional non-ablative skin resurfacing tools, the unique ProDeep Nd:YAP 1340 nm handpiece for the ETHEREA-MX platform allows practitioners to offer a wide array of skin rejuvenation and improvement options. The versatility of this handpiece opens the door for doctors to also treat complicated issues like inflammatory acne with greater efficacy and minimal side effects with little to no downtime.

Fractional treatment delivers a high dose of evenly distributed energy through microscopic treatment zones (MTZs), which generates heat in the subdermal tissue, resulting in deeper collagen remodeling and greater patient satisfaction with less visible erythema. This allows practitioners to effectively treat scars, including acne scars, as well as stretch marks, wrinkles and more, with the ProDeep Nd:YAP 1340 non-ablative laser.

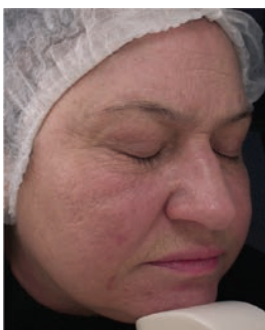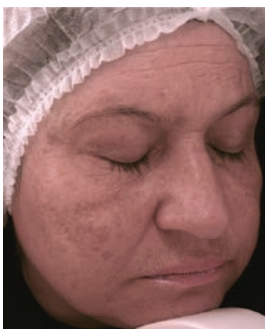Even more exciting, patients can be treated in a shorter amount of time, thanks to the 10 mm square spot shape handpiece that covers a larger treatment area, while the 100 MTZ lens allows high operator visibility and accuracy. In addition, cosmetic surgeons can expand their client base with a wider array of treatments, such as melasma, stretch marks, scars and fractional rejuvenation for mature patients.

According to Valeria Campos, MD, of Clinica Valeria Campos in Jundiai, Sao Paulo, Brazil, her patients enjoy the little to no downtime with the ProDeep. "I use Nd:YAP 1340 with patients who need a better skin treatment, facial rejuvenation and require no downtime."

This laser is the basis for any treatment protocol. It is essential in the doctor's office, Dr. Campos noted. The range of treatments available with ETHEREA-MX allows Dr. Campos to address all of her patients' concerns. "I perform several techniques with the ETHEREA-MX. There are possibilities for several clinical conditions such as cutaneous flaccidity, pore size reduction, bleaching, removal of keratoses, hair treatment, hair vessels, among other treatments that also comprise other specialties, such as vascular problems."

Of course, the ProDeep technology's revolutionary wavelength allows greater depth of penetration, so it more effectively treats striae as well as fine lines and wrinkles, skin resurfacing, most textural irregularities, vascular lesions and cystic acne scars. The high energy dose per MTZ, along with higher subdermal heating, increases efficacy and accelerates the recovery process. But patient results are what counts most.

As Dr. Campos pointed out, "My patients notice results in the first session and are happy because they know that it is only the beginning of many benefits that this technology can do for them." And the ETHEREA-MX technology provides a comprehensive portfolio of aesthetic treatments, "I can promote rejuvenation – from a young patient with more youthful skin that needs only maintenance or prevention – to skin that is already very mature."



Before and after treatment
with ETHEREA-MX
Photos courtesy of Vydence

ProDeep Provides New Approach to Traditional Acne Treatment Methods

By Cindy J. Papp, Contributing Editor

Acne affects millions of people around the world, and according to the *American Academy of Dermatology*, adult acne is on the rise. Sadly, acne and the resulting scars cause many to suffer both aesthetically and psychologically. Today, more people prefer non-pharmaceutical treatments, prompting many patients to turn to procedures such as non-ablative fractional resurfacing.

The innovative 1340 nm Nd:YAP ProDeep handpiece by Vydence (São Carlos, São Paulo, Brazil) is the perfect solution for skin rejuvenation and acne treatment, as it works with the ETHEREA-MX®, a next-generation laser and light-based platform technology. By applying up to 220 mJ per MTZ in fractionated beams, the ProDeep stimulates deeper collagen remodeling where it counts most while remaining gentle enough for the patient to experience a quick recovery.

Anna Tomkowiak, MD, an aesthetic medicine specialist in Wrocław, Poland, uses the ProDeep in her practice to effectively treat acne and acne scarring. “I have a schedule; I do one treatment per month and three to four treatments are needed. If after this time some pimples reappear, I do an extra treatment after three months.”

For even more impressive results, Dr. Tomkowiak gets creative. “I combine all handpieces, especially ProDeep with dual mode, the ipl-sq® handpiece and the INTENSE IR handpiece. The ProDeep is the perfect stimulator. Remodeling appears with time, and the best results are within three months.”

The ProDeep improves acne scars by stimulating the production of new collagen. In addition, it can directly target, heat and shrink sebaceous glands to effectively treat active inflammatory acne. Fractional lasers deliver targeted heat deep into the skin through microthermal treatment zones (MTZs), allowing for precise treatment while surrounding tissue remains unaffected. With the ProDeep, practitioners can provide cooling through the handpiece for the patient’s utmost comfort.

“Treatment is comfortable for the patients especially if we use the cooler,” Dr. Tomkowiak explained. “ProDeep is a non-ablative fractional laser so we not only condition the gland

functioning with energy, but we stimulate skin and the remodeling appears. Patients see the changes, as the quality of their life gets better. The downtime is really short, in most cases patients are back to normal the next day.”

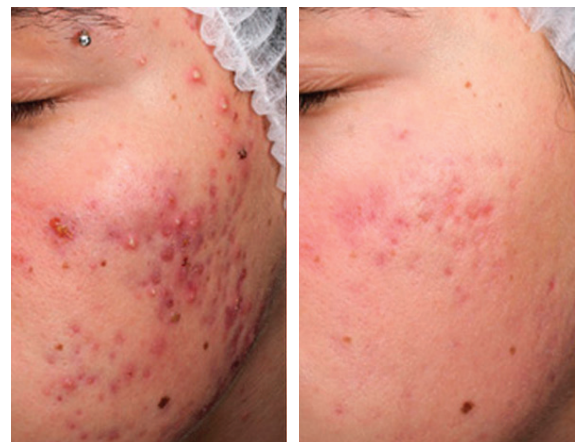While an effective treatment for acne and acne scarring, the rejuvenating benefits of the ProDeep go even further. According to Dr. Tomkowiak, “I also use ProDeep for treating wrinkles, skin tightening, dark circles under the eyes, blackhead removal, stretch marks, hair stimulation and eczema.”

Dr. Tomkowiak has discovered surprising results in other types of cosmetic treatments with the ProDeep. “I also use the ProDeep handpiece for lip enhancement. Not only is the red color of the lips improved, but also structure of the tissue becomes better for older patients as well as smoker’s lines. In some cases, it is better to stimulate the tissue because the filler will not look natural, or I first stimulate the tissue and then use the filler. It is really a perfect treatment for achieving a natural look.”

By enhancing and expanding services, patient satisfaction also increases, and the 1340 nm Nd:YAP ProDeep can help any aesthetic practice increase their portfolio of treatment options. “By working with set protocols, but adjusting therapy to the patient’s skin condition, I can achieve incredible results,” Dr. Tomkowiak shared. “The Etherea MX really satisfies my needs as an aesthetic physician.”



Anna Tomkowiak, MD
Aesthetic Medicine
Specialist
Wrocław, Poland



Before and after five sessions with the ProDeep handpiece
Photos courtesy of Valeria Campos, MD

Nd:YAP 1340 nm for Global Skin Rejuvenation

By Cindy Papp, Contributing Editor

With an exclusive subdermal resurfacing technology for global skin rejuvenation, VYDENCE Medical (Sao Carlos, Brazil) introduces the innovative ProDeep Nd:YAP 1340 nm fractional laser to the family of ETHEREA-MX® handpieces.

Utilizing subdermal non-ablative fractional resurfacing technology, the Nd:YAP 1340 nm can effectively treat a host of skin concerns to satisfy patient demand for non-invasive cosmetic procedures. The ProDeep handpiece enables practitioners to easily treat mild to moderate wrinkles, minimize fine lines and stretch marks, tighten pores and treat acne scarring. With deep penetration targeting water within the cells, the 1340 nm infrared wavelength provides greater efficacy with a shorter recovery time than traditional 1550 nm lasers.

According to Lisa Kellett, MD, FRCPC, a dermatologist in Toronto, Ontario, Canada, the ProDeep handpiece can be used for many types of global skin rejuvenation, even scarring, thanks to its ability to stimulate collagen growth. “It is useful for patients with textural changes such as scars. This improvement in scars is generated by heating the dermis and producing new collagen.”

A larger handpiece surface ensures greater operator visibility and expanded treatment area coverage, as well as improved accuracy. Furthermore, the square shape adds to the efficiency of the Nd:YAP 1340 nm, so the patient can enjoy a shorter treatment time.

Dr. Kellett prefers this larger 8 mm handpiece. “I have the ability to treat acne scars effectively and quickly as the new 8 mm square spot size offers a 25% larger treatment area than a round-spot configuration,” she shared.

Using clinical innovation with power and efficacy, this advanced handpiece also reportedly penetrates deeper than other non-ablative lasers. “The ProDeep can apply up to 220 mJ per MTZ in fractionated beams, which generate more heat in subdermal tissue resulting in deeper collagen remodeling,” Dr. Kellett advised. The result is tighter, smoother skin that looks and feels rejuvenated and fresh.

But what about recovery? The advanced technology ensures treatment is well tolerated by most individuals. Thanks to the deep subdermal penetration, patients experience recovery time of 12 to 24 hours with overall less visible erythema. Aside from mild redness, some patients experience mild edema for up to 12 hours post-treatment. According to Dr. Kellett, “By using the deeper wavelength, patients experience less erythema and can return to normal activities the day after treatment.”

With no consumables, no need for topical anesthesia and no preheating involved, the ProDeep Nd:YAP 1340 nm handpiece is easy to incorporate into any portfolio of treatment options. Its versatility allows the physician to treat a wide variety of skin concerns, affording a larger patient cohort and increased patient satisfaction.

Featuring an impressive range of options, the ETHEREA-MX platform with the ProDeep handpiece enables physicians to deliver global skin rejuvenation. The quality of technology, along with the superior customer support allows physicians to consistently deliver positive and beneficial results to a broader group of patients, while increasing their scope of practice.

“By using the deeper wavelength, patients experience less erythema and can return to normal activities the day after treatment.”

The use of the Er:YAG 2940nm laser associated with amorolfine lacquer in the treatment of onychomycosis*

Uso do laser de Er:YAG 2940nm associado ao esmalte de amorolfina no tratamento da onicomicose

Orlando Oliveira de Morais¹
Ciro Martins Gomes³
Guilherme Marreta Cavalcanti Ayres⁵

Izelda Maria Carvalho Costa²
Dayane Higa Shinzato⁴
Rayane Marques Cardoso⁵

DOI: <http://dx.doi.org/10.1590/abd1806-4841.20131932>

Abstract: Onychomycosis is a common disease, accounting for up to 50% of all unguinal pathologies. We have been developing a clinical trial (ClinicalTrials.gov: NCT01528813) using a 2940nm Er:YAG laser to fractionally ablate human nails in vivo, aiming to increase topical amorolfine lacquer delivery to the nail unit, increasing the efficacy of topical treatment of distal and lateral subungual onychomycosis. Partial results have shown an increase in areas of nail plate free of disease. We believe that ablative lasers can increase the efficacy of topical onychomycosis treatment.

Keywords: Lasers, solid-state; Onychomycosis; Therapeutics

Resumo: A onicomicose é afecção frequente, representando até 50% do total das doenças ungueais. Um ensaio clínico (ClinicalTrials.gov: NCT01528813) em atual desenvolvimento usa o laser de Er:YAG 2940nm para realizar ablação fracionada in vivo de unhas humanas visando aumentar a permeabilidade ungueal ao esmalte de amorolfina, visando aumentar a eficácia do tratamento tópico da onicomicose subungueal distal lateral. Resultados parciais tem demonstrado um aumento na área ungueal livre de doença nas unhas tratadas com o laser, em comparação ao uso isolado do esmalte. Acreditamos que lasers ablativos possam aumentar a eficácia do tratamento tópico da onicomicose.

Palavras-chave: Lasers de estado sólido; Onicomicose; Terapêutica

Onychomycosis is undoubtedly the most common disease affecting the nails, representing up to 50% of all unguinal pathologies.^{1,2} High prevalence of the disease together with the limited efficacy of conventional therapies, has stimulated the development of new and more effective approaches in treating the disease. Promising device-based therapies have been launched on the market over the last few years, such as neodymium-doped yttrium aluminum garnet (Nd:YAG) laser devices.² Despite these advances, few

steps have been taken towards the development of methods that promote nail permeability and the discovery of new effective antifungal drugs.

Laser device systems potentially represent a bright future as regards onychomycosis treatment. Trials with Nd:YAG, titanium sapphire (Ti:Sapphire) and diode lasers have already been developed.² These initial trial results have been impressive, not only due to the high recovery rates achieved, but also the easy, quick and painless administration of lasers to the

Received on 13.06.2012.

Approved by the Advisory Board and accepted for publication on 16.10.2012.

* Study carried out in the Department of Dermatology - University Hospital of Brasilia - University of Brasilia (HUB-UnB) - Brasilia (DF), Brazil.

Conflict of interest: None

Financial Support: None

¹ MD - Dermatologist. MSc. Postgraduate student in Health Sciences - University of Brasilia (UnB) - Brasilia (DF), Brazil.

² PHD - Dermatologist. Adjunct Professor - Department of Dermatology - University of Brasilia (UnB) - Brasilia (DF), Brazil.

³ MD - Dermatologist. Preceptor - Dermatology Residency Program - University Hospital of Brasilia - University of Brasilia (HUB-UnB) - Brasilia (DF), Brazil.

⁴ MD - Ophthalmology Residency Program Student in Ophthalmology - Santa Casa de Campo Grande - Campo Grande (MS), Brazil.

⁵ MD Student - University of Brasilia (UnB) - Brasilia (DF), Brazil.

©2013 by Anais Brasileiros de Dermatologia

affected nails. Nevertheless, the available data on the matter is still incipient and thus further efforts towards the establishment of standard treatment schedules, as well as the best pulse characteristics with regards to fluency, length and format, are still required.²

However, the benefits that traditional abrasion approaches (nail drilling, urea and salicylic acid ointments, etc.) have brought to the treatment of onychomycosis cannot be overlooked.^{3,4} A study of foot care intervention including nail drilling in cases of white superficial and distal lateral subungual onychomycosis, showed improvement in clearing rates achieved with topical treatment, using an electric grinder device.⁴ Exploring the same background, Neev *et al.*, also in 1997, developed an experimental study to evaluate the safety and performance of different lasers in the ablation of human nails.⁵ The 2940nm erbium yttrium aluminum garnet (Er:YAG) laser was found to cause negligible collateral damage to the nail plate, and had one of the best ablation rates among the lasers studied. The Er:YAG laser has intense affinity to water (10-30% of nail plate content), and causes ablation of nails by evaporating the tissue in the same way it does in human skin.⁵

This data, along with the current use of ablative lasers to enhance skin permeation, were the main factors that stimulated the development of a clinical trial at the University of Brasilia, using an Er:YAG laser (Etherea, Industra, São Carlos, Brazil) to fractionally ablate human nails *in vivo*. The study aims to determine the value of the Er:YAG laser as a way of enhancing topical drug delivery (amorolfine lacquer) to the nail plate, by means of clinical improvement in cases of distal and lateral onychomycosis, when compared to the use of amorolfine lacquer alone. We hypothesized that by creating holes through almost the entire thickness of the nail, amorolfine would easily reach subungual hyphae masses and dermatophytomas. Furthermore, larger contact areas for lacquer with nail surfaces would enhance drug permeation to the nail plate.

The study protocol involved patients with hands and feet distal lateral onychomycosis, caused by *T. rubrum* or *T. mentagrophytes*. A single session of the 2940nm Er:YAG laser was applied to the damaged nail plate area, plus a 2 to 3mm adjacent margin of unaffected area. The following settings were used: fluency of 50mJ/mtz, 2ms pulse duration and 1Hz frequency. During laser application to the area in question, the handpiece was kept static so that lasers

beams would always reach coincident points on the surface of the nail plate. Perforated metal sheets were used to narrow laser beams to the target area and protect periungual tissue from damage. The number of pulse shots applied to a same area depended on nail thickness (minimum of 20µm ablation per pulse),⁵ and was limited by patient complaints of pain.

Laser application to nails involved mild discomfort, with patients reporting acute pain and an overheating sensation, lasting up to 5 seconds after pulse shots were interrupted. Mild bleeding running from the area of treatment was a frequent adverse event following damage to the nail bed by the laser.

Given the greater density of keratin and the lower water content in nails compared to skin, it was necessary to apply longer pulses to achieve higher fluency, allowing for greater ablation rates (not shown). With the settings used, the Er:YAG laser was reliable in ablating nail plate areas, although there was large variation in terms of the average number of pulses per nail treated. It occurred mainly due to the differing levels of pain reported among patients, the variation in the extension of affected nail areas, and the degree of subungual hyperkeratosis.

Drawing on the ongoing trial, promising partial results have already been observed (Figure 1). Nails treated with Er:YAG laser plus amorolfine lacquer

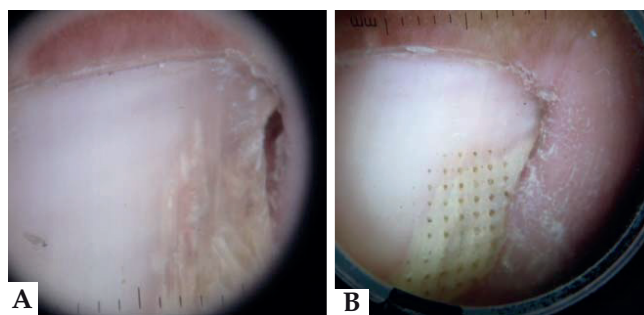


FIGURE 1: Dermoscopy of a nail affected by distal lateral subungual onychomycosis before (A) and after 10 weeks (B) following fractionated ablation by 2940nm Er:YAG laser, followed by weekly use of amorolfine lacquer. Holes on the nail plate surface can be seen, measuring 0.1 to 0.8mm in diameter, 0.2 to 0.5mm apart from each other, as well as an outgrowth of nail plate free of disease (B)

have presented greater clearing rates compared to those treated with amorolfine alone. This data points to the possibility of using ablative lasers as an additional approach to increase the efficacy of onychomycosis topical treatment, and therefore, highlights the need for further investigation in this field. □

REFERENCES

1. Araújo AJG, Bastos OMP, Souza MAJ, Oliveira JC. Occurrence of onychomycosis among patients attended in dermatology offices in the city of Rio de Janeiro, Brazil. *An Bras Dermatol.* 2003;78:299-308.
2. Gupta AK, Simpson FC. New therapeutic options for onychomycosis. *Expert Opin Pharmacother.* 2012;13:1131-42.
3. Di Chiacchio N, Kadunc BV, de Almeida AR, Madeira CL. Nail abrasion. *J Cosmet Dermatol.* 2003;2:150-2.
4. Sumikawa M, Egawa T, Honda I, Yamamoto Y, Sumikawa Y, Kubota M. Effects of foot care intervention including nail drilling combined with topical antifungal application in diabetic patients with onychomycosis. *J Dermatol.* 2007;34:456-64.
5. Neev J, Nelson JS, Critelli M, McCullough JL, Cheung E, Carrasco WA, *et al.* Ablation of human nail by pulsed lasers. *Lasers Surg Med.* 1997;21:186-92.

MAILING ADDRESS:

Orlando Oliveira de Moraes
SGAN 604/605. Av. L2 Norte - Asa Norte
70910-900 - Brasília - DF
Brazil
E-mail: orlando.unb@gmail.com

How to cite this article: Morais OO, Costa IMC, Gomes CM, Shinzato DH, Ayres GMC, Cardoso RM. The use of Er:YAG 2940nm laser associated to amorolfine lacquer in the treatment of onychomycosis. *An Bras Dermatol.* 2013;88(5):847-9.

FRACTIONAL ABLATIVE LASER VERSUS FRACTIONAL ABLATIVE AND COAGULATIVE LASER FOR TREATMENT OF PHOTODAMAGED SKIN IN ARMS AND FOREARMS

Juliana Jordão, Valeria Campos, Talita Santos, Clovis Pinto, Flavia Trevisan, Luisa Pitassi.
Jundiai Medical University and Clínica Valeria Campos. Jundiai, Brazil; UNICAMP. Campinas, Brazil.

SUMMARY: Photodamaged skin in arms and forearms are a common concern in dermatologic offices around the world. Most used treatment options may include topical creams, peeling and non-ablative fractional LASERS, which presents mild to moderate results. On the other hand, ablative LASER systems have shown to achieve the best results and treatment satisfaction also. However, main issue regarding ablative LASERS systems relies on extra-facial areas, once risk of adverse effects caused are significantly increased.

The role of this present study is to compare both the effects of a fractional pure-ablative LASER versus a fractional ablative/coagulative LASER to treat photodamaged skin in arms and forearms, by using low energy dosis in order to prevent side effects.

Twenty patients have received a pure-ablative fractional LASER treatment (also known as *single mode* LASER) in one arm and forearm, and in the other arm and forearm a combination of both ablative/coagulative LASER treatment (also known as DualMode® LASER). Both sides have been treated with a single pass by using a 2940 nm Er:YAG fractional LASER (ETHEREA® 2940 DualMode®, INDUSTRA® Technologies, Brazil), for each patient receiving 2 treatment sessions with 1 month in-between sessions. In single mode 500us pulse width with 10 mJ/MTZ energy was used, and 500us/3ms pulse width with 10 mJ/MTZ and 30 mJ/MTZ energy values for tx in DualMode®. Patients were submitted to a skin biopsy prior to treatment, 1 month after the first and the second treatment session, and 3 months later to the second treatment sessuib. Clinical pictures were taken and recorded for pre-treatment and 3 months post-treatment.

50% of the patients have preferred results obtained in DualMode® treatment sessions. Pain was related to be more intense in this side in all treated patients, as well. All patients noted a clear improvement of skin in both treated sides. Biopsy has shown an epidermal and dermal collagen thickening after treatments, but a more prominent result were observed in DualMode® treated areas. No side effects were noticed in any of chosen and related treatment options.

The use of low energy of fractional pure-ablative and fractional ablative/coagulative LASER are a safe and effective treatment option to treat photodamaged skin in arms and forearms.

BACKGROUND AND OBJECTIVES: A plethora of treatment modalities have been attempted to treat photodamaged skin in arms and forearms, but to date ablative LASERS treatment has been shown to produce a clinically more effective results in many studies. Fractional tissue ablation offers many potential benefits of a whole-surface ablative skin resurfacing, while minimizing adverse effects as well. Er:YAG LASER at 2940 nm wavelength offers a precise tissue ablation with slightly combined coagulative skin damage. DualMode® technology, which combines both hot and cold Erbium fractional ablation and coagulation, also increases Residual Thermal Damage

(RDT) in treated tissue while stimulating neocollagenesis with reduced risk and downtime, specially when compared to another existing and commonly used LASER methods.

This present study intend to evaluate and compare the clinical efficacy of fractional pure-ablative LASER versus fractional ablative/coagulative LASER systems for the treatment of photodamaged skin in arms and forearms, by using low energy dosis in order to prevent side effects.

STUDY DESIGN AND METHODS: Twenty women with moderate to severe photodamaged skin in arms and forearms, including elastosis and lentiginos, aged 39-76 years old, Fitzpatrick Phototype I-III, were selected for this study. 1 of the 20 patients withdrew for non-declared personal reasons.

All patients has received a pure-ablative fractional LASER treatment (also known as *single mode* LASER) in one arm and forearm, and in the other arm and forearm a combination of both ablative/coagulative LASER treatment (also known as DualMode® LASER). Both sides have been treated with a single pass by using a 2940 nm Er:YAG fractional LASER (ETHEREA® 2940 DualMode®, INDUSTRA® Technologies, Brazil), for each patient receiving 2 treatment sessions with 1 month in-between sessions. In single mode 500us pulse width with 10 mJ/MTZ energy was used, and 500us/3ms pulse width with 10 mJ/MTZ and 30 mJ/MTZ energy values for tx in DualMode®. All patients have tolerated the whole treatment sessions, but pain was more significantly intense in single mode treated side, as referred.

Patients were submitted to a skin biopsy prior to treatment, 1 month after the first and the second treatment session, and 3 months later to the second treatment session. Collected samples were fixed in formalin for serial sectioning and staining with *Verhoeff* in preparation for histologic examination. Clinical pictures were taken and recorded for pre-treatment and 3 months post-treatment.

TABLE 1: Parameters and Treatment Guidelines

number of passes	SINGLE MODE
energy	10 mJ/mtz
pulse width	500 µs
spot size	Ø8 mm
energy density	100 mtz/cm ²
number of passes	DUALMODE®
energy	10 mJ/mtz and 30 mJ/mtz
pulse width	500 µs and 3 ms
spot size	Ø8 mm
energy density	100 mtz/cm ²

RESULTS AND CONCLUSION: All twenty subjects have well tolerated the procedure, and a mild to moderate discomfort during treatment was noticed.

Clinical observations and histology findings do also demonstrates that fractional ablative/coagulative 2,940 nm Er:YAG LASER treatment has provided a considerable improvement of photodamaged skin and patient satisfaction. 50% of the patients have preferred results obtained in DualMode® treatment sessions. Main advantage of DualMode® technology for fractional Er:YAG LASERs systems is to provide a full-controlled ablation/coagulation levels in target-tissue, which results in fewer complications and side effects, while improving safety and downtime shortening after each treatment session. There is also minimal to no risk of scarring or hypopigmentation of skin. All patients have noticed a clear improvement in both treated sides. Clinical observations and histological studies also demonstrates a faster tissue re-epithelization and limited adverse side effects. Biopsy has shown an epidermal and dermal collagen thickening after both treatments, but a more prominent results have been observed in DualMode® treated areas. Collagen fibers were intensely (re)grouped in a more significantly organized arrangement in patients treated with DualMode® LASER system. No side effects were noticed in any of chosen and related treatment options.

This present study demonstrates the safe and effective use of low energy of fractional pure-ablative and fractional ablative/coagulative LASERs as a treatment option for photodamaged arms and forearms.

FIGURE 1 • SINGLE MODE BEFORE AND AFTER PHOTOS

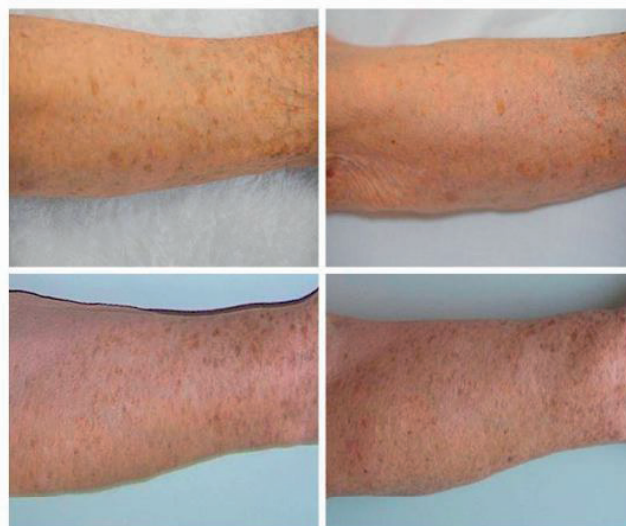
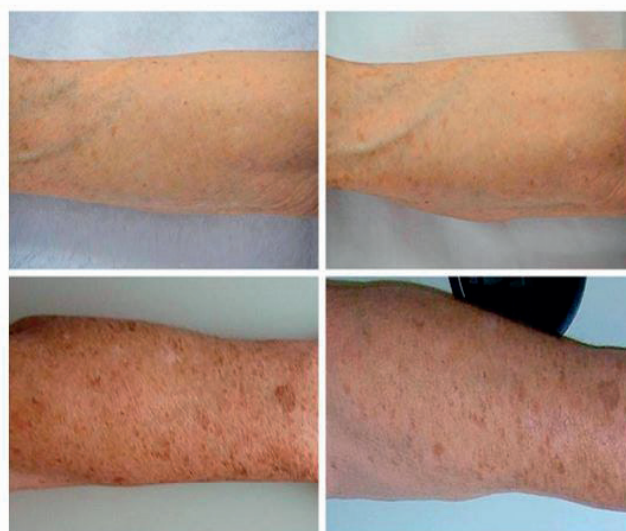
FIGURE 2 • DUALMODE® BEFORE AND AFTER PHOTOS



FIGURES 1-2: clinical pictures demonstrates visible and more pronounced improvement in skin health, tonus and texture as well in DualMode® side.

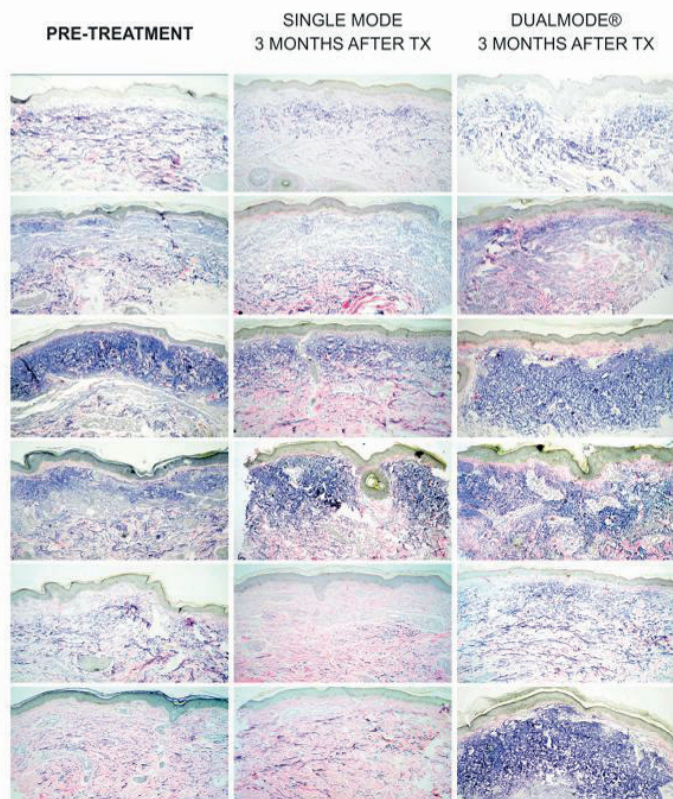


FIGURE 3: Hystological studies revealed that collagen remodeling has been significantly increased 3 months after treatment in all subjects, with a more prominent result were observed in dual mode treated areas. Histology images shown here were stained with Verhoeff.

The effect of vaginal erbium laser treatment on sexual function and vaginal health in women with a history of breast cancer and symptoms of the genitourinary syndrome of menopause: a prospective study

Fernanda Arêas, MD, MSc,¹ Ana L. R. Valadares, MD, PhD,¹ Délio Marques Conde, MD, PhD,² and Lúcia Costa-Paiva, MD, PhD¹

Abstract

Objectives: To assess the effects of vaginal erbium laser treatment on the vaginal health and sexual function of postmenopausal women with a history of breast cancer.

Methods: An open, prospective, therapeutic intervention study was conducted with 24 postmenopausal women with a history of breast cancer and vaginal dryness, and/or dyspareunia, who had not used vaginal hormone therapy for at least 6 months. The women were treated using a 2,940-nm Erbium: YAG laser (Etherea-MX, Athena, São Carlos, São Paulo, Brazil), with 90° and 360° scanning scopes, between August, 2017 and October, 2017 in a private clinic in a city of southeastern Brazil. Vaginal erbium laser treatment was performed at three sessions with a 30-day interval between each session. Sexual function was assessed before and 1 month after treatment using the Short Personal Experiences Questionnaire. Questions related to genitourinary symptoms were also applied. Vaginal health was assessed before each laser session using the Vaginal Health Index Score.

Results: Mean age was 53.7 years. Vaginal health improved, as shown by an increased overall score ($P < 0.001$). The effect size was large between pretreatment and post-treatment scores for vaginal elasticity, fluid volume, epithelial integrity, and moisture. The effect size was also significant for the overall sexual function score and for the score in the dyspareunia domain between pretreatment and 1 month after the final treatment session.

Conclusion: Vaginal erbium laser may represent a novel therapeutic option for improving vaginal health and sexual function in postmenopausal women with a history of breast cancer.

Key Words: Breast cancer – Dyspareunia – Erbium – Menopause – Sexual function – Vulvovaginal atrophy – YAG laser.

Breast cancer is one of the most common forms of cancer in women, with more than 2 million new cases occurring annually worldwide.¹ The survival rate for women with breast cancer is high²; however, many survivors also suffer cancer treatment side effects. Indeed, over 60% of survivors experience at least one urogenital symptom as a sequela of breast cancer treatment.³ This prevalence is probably underestimated because the patient may be embarrassed to discuss these urogenital symptoms with her physician.³

Women with a history of breast cancer are significantly more likely to present with sexual health problems compared with the general population.^{4,5} Broekel et al⁶ reported that sexual function was poorer in breast cancer survivors treated with adjuvant chemotherapy and/or aromatase inhibitors compared with women of a similar age with no history of cancer. The study also showed that vaginal dryness was one of the most important predictors of impaired sexual function in breast cancer survivors.

There are limitations in treating symptoms of vulvovaginal atrophy and dyspareunia in this group of women. Conventional treatments include vaginal moisturizers and lubricants that provide temporary relief.⁷ When there is a consensus between patient and physician, the use of local vaginal hormone therapy may be an option for women whose symptoms fail to improve with nonhormonal treatments.⁸ However, oncologists are often reluctant to prescribe local vaginal hormone therapy, as highlighted by Biglia et al⁹ in a recent study conducted in Italy.

Therefore, novel approaches for the treatment of the genitourinary syndrome of menopause may offer better results for this group of women. Accordingly, the first trials on vaginal erbium laser treatment began in 2012,¹⁰ and since then, many

Received January 8, 2019; revised and accepted March 27, 2019.

From the ¹Department of Gynecology and Obstetrics, State University of Campinas (UNICAMP), Campinas, São Paulo, Brazil; and ²Department of Gynecology and Obstetrics, Federal University of Goiás, Goiânia, Goiás, Brazil.

Funding/support: None reported.

Financial disclosure/conflicts of interest: Vydence Medical provided the laser equipment used in this study.

Address correspondence to: Ana L. R. Valadares, MD, PhD, Department of Gynecology and Obstetrics, State University of Campinas (UNICAMP), Campinas, São Paulo, Brazil; Rua Alexander Fleming, 101, Cidade Universitária Zeferino Vaz, Barão Geraldo, 13083-881 Campinas, São Paulo, Brazil. E-mail: anavaladares@gmail.com

publications have confirmed this approach as a feasible option for the treatment of the genitourinary syndrome of menopause.¹¹⁻¹³

In a recent pilot study,¹⁴ there was a statistically significant difference in dyspareunia, in vaginal dryness, and in the Vaginal Health Index Score between pretreatment and post-treatment with three sessions of vaginal erbium laser therapy in 43 postmenopausal breast cancer survivors with the genitourinary syndrome of menopause ($P < 0.05$). In that study, the women were followed up for 18 months; however, the differences only remained statistically significant for 12 months after the final laser session.

A systematic review and meta-analysis of observational studies¹⁵ showed that sexual function improved consistently after treatment in all four available studies conducted to evaluate vaginal laser therapy in postmenopausal women with genitourinary syndrome. However, all those studies used the ablative fractionated CO₂ laser.

In a systematic review and meta-analysis of randomized clinical trials conducted in 2018,¹⁶ only one of the trials included¹⁷ had assessed the efficacy of the CO₂ laser compared with vaginal estriol and a combination of both treatments (laser + estriol). In the group of women using laser + estriol, there was a significant improvement in the overall Female Sexual Function Index (FSFI) score and in the individual domains of pain, desire, and lubrication. In contrast, in the group submitted to CO₂ laser treatment alone, there was a significant increase in the score for the pain domain of the FSFI. Many previous studies conducted with CO₂ laser have also reported this side effect,¹⁸⁻²³ with one possible explanation being the mode of action of the CO₂ laser. The main difference between the CO₂ laser and the Er: YAG laser lies in their ablative characteristics. Whereas the CO₂ laser works by vaporizing tissue columns,¹⁸ the Er: YAG laser has a smooth-mode technique that creates heat pulses without damaging the mucosa.²⁴

Only two recent nonrandomized studies^{25,26} have assessed sexual function in women with a history of breast cancer after treatment with a CO₂ laser. Both studies reported an improvement in sexual function; however, one²⁵ included only eight women with breast cancer.

Study goals and hypotheses

The objective of the present study was to assess the effects of vaginal erbium laser on the vaginal health and sexual function of postmenopausal women with a history of breast cancer.

The initial hypothesis was that the treatment would improve the following parameters: the overall Vaginal Health Index Score; the individual vaginal health index parameters (vaginal elasticity, fluid volume, epithelial integrity, and moisture); the overall sexual function score; and the individual parameters of sexual function (dyspareunia, arousal, enjoyment, orgasm, and satisfaction with partner as lover)

assessed using the Short Personal Experiences Questionnaire (SPEQ).^{27,28}

METHODS

Study design

An open, prospective, therapeutic intervention study was conducted.

Participants

Thirty women with a history of breast cancer and complaints of dyspareunia and/or vaginal dryness were selected at gynecological and oncological clinics in a city of southeastern Brazil. The study investigators contacted these women by telephone, with 25 meeting the inclusion and exclusion criteria. One woman dropped out of the study for family reasons; therefore, the final sample consisted of 24 women.

Eligibility required a personal history of breast cancer, complaints of dyspareunia and/or vaginal dryness, and to have had no menstruation for at least 1 year. The exclusion criteria were: having used systemic or vaginal hormone therapy in the preceding 6 months, severe psychiatric problems, a history of vaginismus, vaginal bleeding or unexplained vulvar lesion, active or recent scars in the genital area (in the previous 30 days), a urinary tract infection in the preceding 30 days, having used lubricants or any local preparations in the previous 30 days, photosensitivity or use of photosensitizing drugs, second or third-degree genital prolapse according to the Pelvic Organ Prolapse Quantification System, and any chronic or severe disease that could compromise the study evaluation. Before their inclusion in the study, the eligible women were provided with information on the nature of the study in a private setting, were given the opportunity to ask any questions, and were then asked to sign an informed consent form.

The study protocol was approved by the institutional review board under registration number CAAE 60580316.0.0000.5143. All patients gave their written consent for participation in the study.

Therapeutic interventions and procedures

The women selected as possible candidates for inclusion in the study were invited by telephone to attend three vaginal laser sessions in a private clinic in a city in southeastern Brazil. The study was performed between August, 2017 and November, 2017.

Immediately before the first laser session, women completed a self-administered questionnaire containing 100 questions on their sociodemographic conditions, health habits, sexual aspects (SPEQ),^{27,28} urogenital symptoms, and health issues. Next, two of the investigators together performed a speculum examination to calculate the woman's Vaginal Health Index Score. After this evaluation, the vaginal wall was anesthetized using a tampon soaked in 4% lidocaine for 30 minutes. The tampon was then removed and the excess anesthetic was washed away using saline solution.

The vaginal laser used was a 2,940-nm Erbium: YAG laser (Etherea-MX, Athena, São Carlos, São Paulo, Brazil), with 90° and 360° scanning scopes. After inserting the specific fenestrated speculum for the procedure, the 360° scanning scope was inserted into the speculum, hence not in direct contact with the vaginal mucosa. The vaginal wall was irradiated at 360° with four pulses every 5 mm (using the scale at the tip of the device). This procedure was repeated three times up to the entrance of the vaginal canal. The parameters used²⁹ for this collimated tip were: fluency (laser energy supplied per area unit) 2.0 J/cm², frequency 0.5 Hz, pulses using the smooth-mode technique (eight pulse trains of 50 ms totaling 400 ms), that is, long pulses with a very large quantity of photons, but low heat. This process does not generate vaporization; it merely heats the tissue and helps stimulate collagen production without causing necrosis.²⁴

After removing the first scanning scope, the 90° scope was inserted into the speculum. The anterior vaginal wall was irradiated with four pulses every 10 mm (using the scale at the tip of the device). This procedure was repeated three times up to the entrance of the vaginal canal, rotating the speculum at the 11, 12, and 1 o'clock positions. The parameters used for this collimated tip were: fluency (laser energy supplied per area unit) 35 mJ/MTZ, frequency 0.5 Hz, pulses in accordance with the smooth-mode technique.

All women were submitted to three laser sessions (T0, L2, L3) at 30-day intervals. One month after the last session (L3 + 1), the women returned to the clinic to complete a further questionnaire on sexual function (SPEQ).^{27,28}

Data collection and measurement instruments

Vaginal health

Vaginal health was assessed by speculum examination immediately before each laser session and, the Vaginal Health Index Score was calculated. The Vaginal Health Index Score assesses the vaginal mucosa (elasticity, fluid volume and consistency, pH, epithelial integrity, and moisture). Each parameter is rated from 1 to 5. If the total score is ≤ 15 , the vagina is considered atrophic.³⁰ All the women were examined by the same two physicians, together, and a consensus was reached on all the parameters evaluated.

Sexual function

Sexual function was assessed just before the first laser session and again 1 month after the three sessions, using the self-administered SPEQ.^{27,28} The sexual function score is calculated using the mean sum of the scores for enjoyment (a score of 1-6, where 1 = no enjoyment and 6 = maximum enjoyment); arousal (1-6); orgasm (1-6); frequency of intercourse (1-5, where 1 = never, 2 = less than once a week, 3 = once or twice a week, 4 = several times a week, and 5 = once a day or more); and desire (1-5). A score ≤ 7 was considered indicative of sexual dysfunction, whereas a score > 7 indicated an absence of sexual dysfunction.^{27,28} Each component of the sexual function score was also analyzed individually. In addition, other sexual variables were also

assessed using this questionnaire: dyspareunia (a score of 1-6); satisfaction with partner as a lover (a score of 1-6); satisfaction with partner as a friend/human being (score 1-6); and partner's sexual problems (score 1-6).

Statistical analysis

Sample size was calculated using G*Power Version 3.1.2^{31,32} and was based on a previous pilot study¹⁴ conducted with women with a history of breast cancer. Calculation took into consideration the difference between a mean Vaginal Health Index Score of 8.1 ± 1.3 at baseline and 20.0 ± 1.0 after 4 months of treatment in a single group, for an alpha error of 0.05 and a beta error of 0.2.

The McNemar test of symmetry (for two categories) and the Bowker test of symmetry (for three or more categories) were used to compare categorical variables between the initial (pretreatment) and final (post-treatment) assessments. The Wilcoxon test was used to compare numerical variables between the initial and final assessments. The Friedman test was used to compare the Vaginal Health Index Score at the three evaluation moments. Significance level was defined at 5%. Cohen's d ³³ was used to measure the effect size of the Vaginal Health Index Score parameters and SPEQ domains between baseline and post-treatment. Cohen's d and odds ratios (ORs) were used to evaluate the effect size of the overall SPEQ score between baseline and post-treatment.³³

The SAS (Statistical Analysis System) software program for Windows, version 9.2 (SAS Institute Inc., 2002-2008, Cary, NC) was used throughout the statistical analysis.

RESULTS

All 24 women admitted to the study completed the three treatment sessions and were included in the analysis. The mean age of the women was 53.67 ± 9.66 years (\pm SD), and the mean number of years since menopause was 7.92 ± 5.94 years. Half the women had been diagnosed with breast cancer less than 5 years previously, 65% had undergone chemotherapy, and 60% were still undergoing cancer therapy. Of these, 60% were using tamoxifen, with 70% having used the drug for over a year.

The mean Vaginal Health Index Score increased significantly between pretreatment and the first and second laser sessions. The score changed from 11.88 ± 4.88 at baseline (immediately before T0) to 15.63 ± 3.75 after 30 days of the first laser session (immediately before L2) and further increased to 17.38 ± 4.55 after 30 days of the second laser session (immediately before L3) ($P < 0.001$; Fig. 1).

When each parameter of the vaginal health index was analyzed separately, a large effect size was found between baseline and 30 days after the second laser session (immediately before L3) for elasticity (Cohen's $d = 1.10$), fluid volume and consistency (Cohen's $d = 1.21$), epithelial integrity (Cohen's $d = 1.86$), and moisture (Cohen's $d = 1.24$) (Table 1).

The SPEQ sexual function score, dichotomized into ≤ 7 (sexual dysfunction) and > 7 (no sexual dysfunction), and assessed before treatment (T0) and 1 month after the third

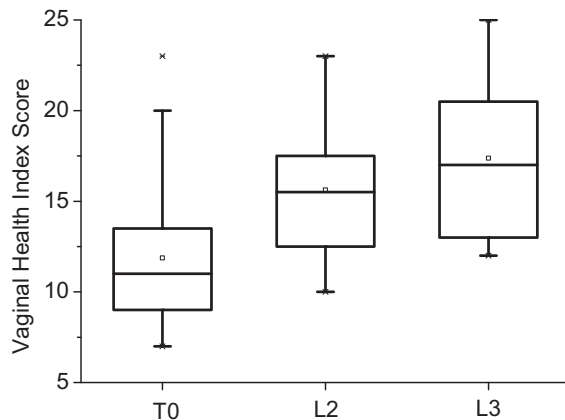


FIG. 1. Vaginal Health Index Score before and after two vaginal erbium laser sessions (n = 24). T0, immediately before the first session; L2, immediately before the second session; L3, immediately preceding the third session; VEL: vaginal Erbium laser; VHIS, Vaginal Health Index Score. $P < 0.001$: 1≠2, 1≠3, 2≠3. P value refers to Friedman test for comparison of VHIS between three sessions.

laser session (L3+1), showed a large effect size (Cohen’s $d = 0.39$, OR 8.00) and a statistically significant improvement between pretreatment and post-treatment ($P = 0.04$) (Table 2).

Table 3 shows the individual analysis for each SPEQ component in which the baseline results were compared with those obtained following treatment. There was a large effect size (Cohen’s $d = 0.95$) and a statistically significant improvement ($P = 0.01$) in dyspareunia. A medium effect size was found between pretreatment values and values found 1 month after the third laser session for: arousal (Cohen’s $d = 0.73$), enjoyment (Cohen’s $d = 0.62$), orgasm (Cohen’s $d = 0.56$), and satisfaction with partner as a lover (Cohen’s $d = 0.72$). In addition, there was a statistically significant improvement in these sexual parameters ($P < 0.05$).

Complications recorded during laser treatment included vaginal candidiasis (one woman) and acute cystitis (one woman) after the first session. These complaints were successfully treated before the second session.

DISCUSSION

According to the results of this study, the vaginal 2,n940-nm Erbium: YAG laser appears to exert a beneficial effect on

vaginal health and sexual function in postmenopausal women with a history of breast cancer.

Vaginal health

Despite the small sample size in the present study, there were statistically significant differences and a large effect size between baseline results and those found 1 month after the second laser session for the vaginal health index parameters of vaginal elasticity, fluid volume and consistency, epithelial integrity, and moisture. Effect size is considered an essential complement of statistical significance because it differentiates between the significant statistical value and its practical importance.³⁴ There was a statistically significant improvement in vaginal atrophy, as measured by the Vaginal Health Index Score, between pre and post-treatment. These vaginal parameters were objectively analyzed by two trained medical doctors, who, working in conjunction, performed speculum examinations on all the women, thus providing much more reliable results and reducing any possible observation bias. Although there were three vaginal erbium laser sessions, as described in previous studies,¹¹⁻¹⁴ it proved impossible to assess vaginal health 1 month after the third session due to difficulties in scheduling another speculum examination. Some studies in the literature, however, suggest that the improvement in vaginal health is more significant 1 month after the third laser session.¹¹⁻¹⁴

In the present study, no statistically significant difference was found in vaginal pH between baseline and the final laser treatment. As a decrease in vaginal pH depends on a cascade of events,³⁵ at the moment of evaluation, there had been insufficient time for the microbial lactobacillus flora to have been restored.

Hormonal changes during menopause may harm the standard structure and function of the genital tissues, with a consequent effect on vasoconstriction, lubrication, smooth muscle relaxation, and vaginal microbiota.³⁶ Mucosal hydration is reduced in the dermis, consequently reducing intercellular mucopolysaccharide and hyaluronic acid.³⁷ The laser has a photothermal effect, which could induce trophic changes in the vaginal mucosa, as shown by the histological findings reported by Gaspar et al.³⁸

Sexual function

There was a large effect size in the overall SPEQ score between baseline and 1 month after the third vaginal erbium

TABLE 1. Components of the Vaginal Health Index before and after two sessions of vaginal erbium laser (n = 24)

	T0	L2	L3	Effect size	P
Vaginal elasticity	2.67 ± 0.87	3.04 ± 0.86	3.58 ± 0.72	1.10	<0.001
Fluid volume and consistency	2.0 ± 0.83	2.67 ± 0.92	3.17 ± 1.20	1.21	<0.001
Vaginal pH	2.25 ± 1.73	2.79 ± 1.67	2.63 ± 1.76	0.34	0.06
Epithelial integrity	2.58 ± 0.97	3.83 ± 0.64	4.21 ± 0.59	1.86	<0.001
Moisture	2.38 ± 1.21	3.29 ± 0.91	3.79 ± 0.98	1.24	<0.001

L2, immediately before the second session; L3, immediately preceding the third session; T0, immediately before the first session. P value refers to Friedman test used to compare the vaginal health index components between the three laser sessions. Effect size for paired test: Cohen’s d . Values are mean ± SD (standard deviation).

TABLE 2. Short Personal Experiences Questionnaire (SPEQ) score before and after vaginal erbium laser treatment (n = 24)

SPEQ score	T0, n (%)	L3 + 1, n (%)
≤7 (sexual dysfunction)	15 (62.5)	8 (33.3)
>7 (no sexual dysfunction)	9 (37.5)	16 (66.7)

L3 + 1, 1 month after the last vaginal erbium laser session; T0, before vaginal erbium laser.
P = 0.04 refers to the McNemar test for comparison of the SPEQ score between pre and post-treatment. Effect size refers to Cohen’s *d* = 0.39 and odds ratio = 8.00.

laser session. There was also a significant effect size for the decrease in dyspareunia. A moderate effect size was found for arousal, enjoyment in sexual activities and orgasm, and with the woman’s satisfaction with her partner as a lover. Such a positive effect is probably related to the restoration of genital tissues and consequent relief from urogenital symptoms.¹⁸

The clinical expression of sexual symptoms at menopause is influenced by several factors, ranging from significantly lower estrogen and androgen levels to intrapersonal and interpersonal factors.³⁹The hemodynamic process of sexual arousal involves peripheral neurovascular function and pelvic floor muscles, and is closely linked to the biomechanical and viscoelastic properties of the vaginal wall.⁴⁰ In women with vulvovaginal atrophy, distention of the vaginal introitus is difficult, as is lubrication in response to sexual stimuli. Consequently, the vaginal canal is shorter and narrower, and these women may experience painful and/or unpleasant sexual intercourse.⁴¹

As reported in previous studies,¹¹⁻¹⁴ vaginal erbium laser reduces atrophy of the vaginal mucosa and restores genital tissues, relieving urogenital symptoms and exerting a secondary effect on these women’s sexual function.

In the present study, laser treatment failed to improve sexual desire. However, laser treatment was not expected to directly affect libido because female sexual desire is complex and results from the interaction of biological (neuroendocrine) components, and also beliefs and values.⁴²

In addition, vaginal erbium laser treatment had no effect on the frequency of sexual activity. A variety of factors have

been associated with the frequency of sexual activity in menopausal women, suggesting that an individualized approach is needed for any improvement in sexual activity to be achieved.⁴³

One of the limitations of the present study is that there is no control group. However, some previous studies^{11,13,38} compared the use of vaginal erbium laser with the standard treatment for the genitourinary syndrome of menopause (vaginal estriol) in women with no history of breast cancer. The results achieved after laser therapy were similar to those obtained with the use of localized estrogen therapy, with the advantage that the results achieved in the laser group were maintained for 12 months after treatment discontinuation, unlike the results obtained by the women in the estriol group. It is also essential to recognize that the mechanism of action in laser therapy is probably different from that of estriol, resulting in the development of new vessels, reconstitution of the lamina propria, and, consequently, leading to long-lasting regeneration of the vaginal mucosa, even after the end of treatment.³⁸

Another potential limitation of the present study is that it is impossible to guarantee that the women did not use any vaginal products during the study period, despite explicit instructions to avoid them. Postmenopausal women with symptoms related to the genitourinary syndrome of menopause widely use over-the-counter lubricants as a personal strategy to relieve pain during sexual intercourse.³⁹ The use of vaginal moisturizers or lubricants before the laser procedure could improve fluid retention in the tissues. As the erbium laser has a high affinity for water, previously hydrated mucosa could increase the thermal laser effect, with a consequently positive effect on results.

The follow-up period in the present study was short, only 30 days after the end of the final laser session; however, a published study with a 24-month follow-up⁴⁴ suggests that dyspareunia, vaginal lubrication, and improvements in vaginal health continue for up to 12 months. Based on that study⁴⁴ and because vaginal erbium laser is a safe and noninvasive procedure, treatment could be repeated annually or as soon as women begin to experience symptoms again, thus maintaining the beneficial effect on vaginal mucosa.

TABLE 3. Components of the Short Personal Experiences Questionnaire before and after vaginal erbium laser (n = 24)

	T0	L3+1	Effect size	<i>P</i>
Frequency of intercourse	2.17 ± 0.89	2.35 ± 0.88	0.35	0.219
Desire	1.96 ± 0.77	2.26 ± 0.86	0.43	0.092
Arousal	2.18 ± 1.56	3.23 ± 1.63	0.73	0.004
Enjoyment	2.73 ± 1.80	3.64 ± 1.73	0.62	0.012
Orgasm	2.59 ± 1.89	3.4 ± 1.82	0.56	0.022
Satisfaction with partner as lover	3.84 ± 1.86	4.74 ± 1.69	0.72	0.004
Satisfaction with partner as friend/human being	4.52 ± 1.60	4.90 ± 1.41	0.39	0.125
Partner’s sexual problems	2.58 ± 1.84	2.74 ± 1.91	0.08	0.947
Dyspareunia	3.46 ± 1.66	2.23 ± 1.30	0.95	0.012

P value refers to Wilcoxon test; effect size for paired test: Cohen’s *d* for comparison of pre and post-treatment values. Values are mean ± SD (standard deviation).

L3 + 1, 1 month after the last vaginal erbium laser session; T0, before vaginal erbium laser.

The maintenance of sexual activity is a component of life satisfaction and successful aging,⁴⁵ and, although laser therapy is not considered a definitive cure for the genitourinary syndrome of menopause, the results of this study suggest that this is a viable option for the treatment of vaginal atrophy and sexual dysfunction in women with a history of breast cancer. Furthermore, studies on laser therapy for the treatment of the genitourinary syndrome of menopause in women with this particular profile are few; therefore, one of the strengths of the present study is that it is the first to assess the effect of vaginal erbium laser therapy on the sexual function of women with a history of breast cancer.

CONCLUSIONS

The present study showed that vaginal applications of the 2,940-nm Erbium: YAG laser are associated with an improvement in sexual function and vaginal atrophy in postmenopausal women with a history of breast cancer. These results may have been achieved by improving the symptoms of the genitourinary syndrome of menopause. The long-term effects of the use of this technology on vaginal tissue should be investigated in future studies with longer follow-up periods and also in randomized clinical trials.

REFERENCES

- Bray F, Ferlay J, Soerjomataram I, Siegel RL, Torre LA, Jemal A. Global cancer statistics 2018: GLOBOCAN estimates of incidence and mortality worldwide for 36 cancers in 185 countries. *CA Cancer J Clin* 2018;68:394-424.
- National Cancer Institute. SEER Cancer Statistics Review 1975-2015; 2017. Available at: https://seer.cancer.gov/csr/1975_2015/. Accessed September 10, 2018.
- Chin SN, Trinkaus M, Simmons C, et al. Prevalence and severity of urogenital symptoms in postmenopausal women receiving endocrine therapy for breast cancer. *Clin Breast Cancer* 2009;9:108-117.
- Mortimer JE, Boucher L, Baty J, Knapp DL, Ryan E, Rowland JH. Effect of tamoxifen on sexual functioning in patients with breast cancer. *J Clin Oncol* 1999;17:1488-1492.
- Farthmann J, Hanjalic-Beck A, Veit J, et al. The impact of chemotherapy for breast cancer on sexual function and health-related quality of life. *Support Care Cancer* 2016;24:2603-2609.
- Broekel JA, Thors CL, Jacobsen PB, Small M, Cox CE. Sexual functioning in long-term breast cancer survivors treated with adjuvant chemotherapy. *Breast Cancer Res Treat* 2002;75:241-248.
- Cohen PA, Brennan A, Marino JL, Saunders CM, Hickey M. Managing menopausal symptoms after breast cancer: a multidisciplinary approach. *Maturitas* 2017;105:4-7.
- American College of Obstetricians and Gynecologists' Committee on Gynecologic Practice, Farrell R. ACOG Committee Opinion No. 659: the use of vaginal estrogen in women with a history of estrogen-dependent breast cancer. *Obstet Gynecol* 2016;127:e93-e96.
- Biglia N, Bounous VE, D'Alonzo M, et al. Vaginal atrophy in breast cancer survivors: attitude and approaches among oncologists. *Clin Breast Cancer* 2017;17:611-617.
- Vizintin Z, Rivera M, Fistonic I, et al. Novel minimally invasive VSP Er: YAG laser treatments in gynecology. *J Laser Health Acad* 2012;1:46-58.
- Gambacciani M, Levancini M, Cervigni M. Vaginal erbium laser: the second-generation thermotherapy for the genitourinary syndrome of menopause. *Climacteric* 2015;18:757-763.
- Gambacciani M, Torelli MG, Martella L, et al. Rationale and design for the Vaginal Erbium Laser Academy Study (VELAS): an international multicenter observational study on genitourinary syndrome of menopause and stress urinary incontinence. *Climacteric* 2015;18 (Suppl 1):43-48.
- Gambacciani M, Palacios S. Laser therapy for the restoration of vaginal function. *Maturitas* 2017;99:10-15.
- Gambacciani M, Levancini M. Vaginal erbium laser as second-generation thermotherapy for the genitourinary syndrome of menopause: a pilot study in breast cancer survivors. *Menopause* 2017;24:316-319.
- Pitsouni E, Grigoriadis T, Falagas ME, Salvatore S, Athanasiou S. Laser therapy for the genitourinary syndrome of menopause: a systematic review and meta-analysis. *Maturitas* 2017;103:78-88.
- Pitsouni E, Grigoriadis T, Douskos A, Kyriakidou M, Falagas ME, Athanasiou S. Efficacy of vaginal therapies alternative to vaginal estrogens on sexual function and orgasm of menopausal women: a systematic review and meta-analysis of randomized controlled trials. *Eur J Obstet Gynecol Reprod Biol* 2018;229:45-56.
- Cruz VL, Steiner ML, Pompei LM, et al. Randomized, double-blind, placebo-controlled clinical trial for evaluating the efficacy of fractional CO2 laser compared with topical estriol in the treatment of vaginal atrophy in postmenopausal women. *Menopause* 2018;25: 21-28.
- Salvatore S, Nappi RE, Parma M, et al. Sexual function after fractional microablative CO2 laser in women with vulvovaginal atrophy. *Climacteric* 2015;18:219-225.
- Salvatore S, Athanasiou S, Candiani M. The use of pulsed CO2 lasers for the treatment of vulvovaginal atrophy. *Curr Opin Obstet Gynecol* 2015;27:504-508.
- Pieralli A, Fallani MG, Becorpi A, et al. Fractional CO2 laser for vulvovaginal atrophy (VVA) dyspareunia relief in breast cancer survivors. *Arch Gynecol Obstet* 2016;294:841-846.
- Salvatore S, Nappi RE, Zerbinati N, et al. A 12-week treatment with fractional CO2 laser for vulvovaginal atrophy: a pilot study. *Climacteric* 2014;17:363-369.
- Athanasiou S, Pitsouni E, Antonopoulou S, et al. The effect of microablative fractional CO2 laser on vaginal flora of postmenopausal women. *Climacteric* 2016;19:512-518.
- Sokol ER, Karram MM. Use of a novel fractional CO2 laser for the treatment of genitourinary syndrome of menopause: 1-year outcomes. *Menopause* 2017;24:810-814.
- Vizintin Z, Lukac M, Kazic M, Tettamanti M. Erbium laser in gynecology. *Climacteric* 2015;18 (Suppl 1):4-8.
- Gittens P, Mullen G. The effects of fractional microablative CO2 laser therapy on sexual function in postmenopausal women and women with a history of breast cancer treated with endocrine therapy. *J Cosmet Laser Ther* 2018;1-5; doi: 10.1080/14764172.2018.1481510.
- Becorpi A, Campisciano G, Zanotta N, et al. Fractional CO2 laser for genitourinary syndrome of menopause in breast cancer survivors: clinical, immunological, and microbiological aspects. *Lasers Med Sci* 2018;33:1047-1054.
- Dennerstein L, Leher P, Dudley E. Short scale to measure female sexuality: adapted from McCoy Female Sexuality Questionnaire. *J Sex Marital Ther* 2001;27:339-351.
- Valadares AL, Pinto-Neto AM, de Sousa MH, Osis MJ. [Sociocultural adaptation of the short personal experiences questionnaire (SPEQ) in Brazil.]. *Rev Bras Ginecol Obstet* 2010;32:72-76.
- Vydence medical. Guia de referência clínica Etherea-MX[®] Athena[®], 1^ª edição [Etherea-MX[™] Athena[™] Clinical Reference Guide, 1st Edition]. São Paulo; 2018.
- Bachmann GA, Notelovitz M, Kelly SJ, Thompson C. Long-term non-hormonal treatment of vaginal dryness. *Clin Pract Sexual* 1992;8:3-8.
- Faul F, Erdfelder E, Buchner A, Lang AG. *G*Power Version 3.1.2 [computer software]*. Germany: Universität Kiel; 2008.
- Hulley SB, Cummings SR. *Designing Clinical Research*. Baltimore: Williams & Wilkins; 1988; pp. 148 and 215.
- Cohen J. *Statistical Power Analysis for the Behavioral Sciences*, 2nd ed. Hillsdale, NJ: Lawrence Erlbaum Associates; 1988.
- Cano-Corres R, Sánchez-Álvarez J, Fuentes-Arderiu X. The effect size: beyond statistical significance. *EJIFCC* 2012;23:19-23.
- Mac Bride MB, Rhodes DJ, Shuster LT. Vulvovaginal atrophy. *Mayo Clin Proc* 2010;85:87-94.
- Palacios S. Managing urogenital atrophy. *Maturitas* 2009;63:315-318.
- Calleja-Agius J, Brincat MP. Urogenital atrophy. *Climacteric* 2009;12: 279-285.
- Gaspar A, Brandi H, Gomez V, Luque D. Efficacy of Erbium:YAG laser treatment compared to topical estriol treatment for symptoms of genitourinary syndrome of menopause. *Lasers Surg Med* 2017;49:160-168.

VAGINAL ERBIUM LASER AFTER BREAST CANCER

39. Nappi RE. New attitudes to sexuality in the menopause: clinical evaluation and diagnosis. *Climacteric* 2007;10 (Suppl 2):105-108.
40. Nappi RE, Palacios S. Impact of vulvovaginal atrophy on sexual health and quality of life at postmenopause. *Climacteric* 2014;17:3-9.
41. Sturdee DW, Panay N; International Menopause Society Writing Group. Recommendations for the management of postmenopausal vaginal atrophy. *Climacteric* 2010;13:509-522.
42. Kingsberg SA. The impact of aging on sexual function in women and their partners. *Arch Sex Behav* 2002;31:431-437.
43. Smith RL, Gallicchio L, Flaws JA. Factors affecting sexual activity in midlife women: results from the midlife health study. *J Womens Health* 2017;26:103-108.
44. Gambacciani M, Levancini M, Russo E, Vacca L, Simoncini T, Cervigni M. Long-term effects of vaginal erbium laser in the treatment of genitourinary syndrome of menopause. *Climacteric* 2018;21:148-152.
45. Woloski-Wruble AC, Oliel Y, Leefsma M, Hochner-Celnikier D. Sexual activities, sexual and life satisfaction, and successful aging in women. *J Sex Med* 2010;7:2401-2410.

Combination Therapies: Laser-Assisted Delivery of 5-Fluorouracil

Ablative fractional laser-assisted drug delivery optimizes the cutaneous permeation of drugs by tissue ablation, that is, by removing the stratum corneum and the superficial layers of the skin.¹ The use of ablative fractional lasers to deliver 5-fluorouracil (5-FU) has been described in the literature for the treatment of squamous cell carcinoma (SCC) in situ, including actinic keratosis (AK), and basal cell carcinoma (BCC).^{2,3} We report 2 cases in which this technique was used for the treatment of field cancerization.

An 88-year-old woman with multiple AKs on the nose received a single session of Er:YAG laser ablation (Etherea, Vydence Medical, São Paulo, Brazil) at a wavelength of 2,940 nm, with a spot size of 8 mm, at 100 MTZ/cm², in a single mode (500 μ s), and with 12.5 mJ/MTZ, followed by irrigation with saline to remove debris. An anhydrous serum with a combination of 5% 5-FU plus 2% alpha-bisabolol was then applied (drug delivery). The patient was instructed to apply the formulation for 6 nights after the procedure. She had an excellent clinical response, and the improvement was maintained after 9 months of follow-up (Figure 1A,B).

A separate 77-year-old man with multiple AKs on the face and scalp received a single session of Er:YAG laser ablation (Etherea, Vydence) at a wavelength of 2,940 nm, with a spot size of 8 mm, at 100 MTZ/cm², in a single mode (500 μ s), and with 12.5 mJ/MTZ, followed by irrigation with saline. Immediately after the procedure, an anhydrous serum with a combination of 5% 5-FU plus 2% alpha-bisabolol was applied, and the patient was instructed to repeat the application for 6 nights after the procedure. There was complete lesion clearance and improvement of skin quality, which were maintained for 9 months after treatment (Figure 2A,B).

Discussion

Enhanced skin penetration of 5-FU may be useful in the topical treatment of nonmelanoma skin cancer and AK. Strategies available for this purpose include the use of occlusion, liposomes, microneedles, iontophoresis, electroporation, and laser.⁴ Ablative fractional laser-assisted drug delivery occurs through microscopic ablated channels surrounded by thin coagulated zones, which facilitates the absorption of topical drugs when the drug is applied immediately after the laser procedure. The ablated channels are more permeable during the first hour after the procedure, gradually reducing their permeability within the first 24 hours.⁵ Laser parameters can be adjusted to control the microchannel dimensions as well as the depth and distance between the channels. For hydrophilic drugs, such as 5-FU, these adjustments depend on the site where the drug is meant to be delivered because the depth of drug penetration is dependent on the laser-channel depth.⁴ In addition, for small hydrophilic drugs, the coagulation zone acts as a drug reservoir, gradually delivering 5-FU into the skin during the hours after the laser procedure.⁴

Actinic keratoses are chronic lesions that occur on the sun-exposed skin and develop on a background of field cancerization, in which clinical and subclinical lesions are present. All AKs must be treated, since they can progress to invasive skin cancer. 5-FU is a well-documented treatment for AKs, which acts through an interference in DNA synthesis by irreversibly inactivating thymidylate synthase, and the final result is the death of rapidly proliferating cells. Skin reactions to 5-FU during the 4-week application period are dependent on patient adherence to treatment. For this reason, the use of ablative fractional lasers to enhance the transepidermal delivery of 5-FU is beneficial to achieve the maximal antitumor effect with

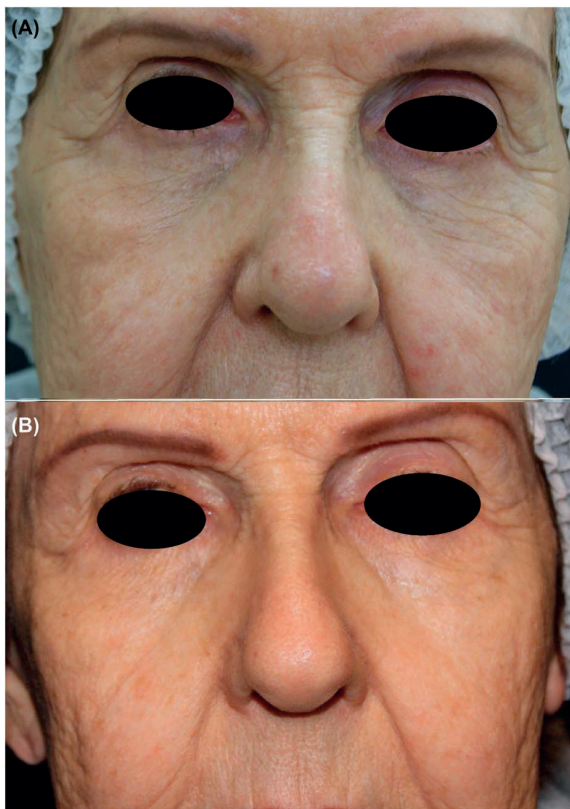


Figure 1. Multiple actinic keratoses on the dorsum of the nose (A). Excellent response after 1 session of Er:YAG laser ablation (2,940 nm) and delivery of 5-fluorouracil 9 months after the procedure (B).

a significant reduction in the treatment duration.¹ As observed in our 2 cases, excellent results were obtained

after a single laser session followed by only 1 week of 5-FU. Also, with the laser parameters used in the present report, only the stratum corneum was removed; by doing so, the procedure overcomes the main barrier for transepidermal drug delivery and ensures that 5-FU is delivered into the deeper epidermal layers, allowing for the treatment of AK with extensive keratinocyte dysplasia.⁴ Glenn and colleagues³ described the use of ablative fractional CO₂ laser for 5-FU delivery, in a single session, on the forearms of a patient with severely actinic damaged skin. Nguyen and colleagues investigated the use of ablative fractional laser-assisted topical 5-FU for BCC and SCC in situ, applied daily for 7 days, under occlusion, and reported histologic clearance in 87% of the 30 treated lesions, with no serious adverse effects. Although some authors suggest that classic local reactions after application of topical 5-FU may be intensified with the use of drug delivery techniques, Nguyen and colleagues² reported only erythema and mild erosion.

An anhydrous serum was the vehicle of choice for the delivery of the 5-FU formulation reported in this study because of its low viscosity, which allows occlusion and potentiates drug permeation. Also, this vehicle is free of preservatives that can cause contact dermatitis and allergic granulomatous reaction.

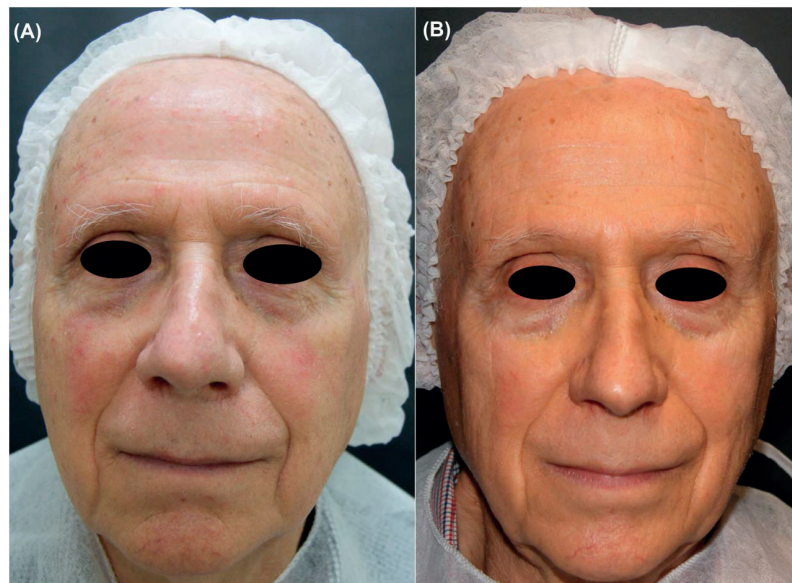

Figure 2. Multiple actinic keratoses on the face (A). Excellent response after 1 session of Er:YAG laser ablation (2,940 nm) and delivery of 5-fluorouracil 9 months after the procedure (B).

Conclusion

The authors indicate the use of this drug delivery technique to optimize the penetration of essential medications in dermatology and to reduce the duration of treatment, which was reduced to 1 week in the 2 cases using 5-FU reported here. The effectiveness and safety of 5-FU have been extensively studied and are well documented in the literature for a variety of clinical conditions; however, large clinical studies on the safety profile and tolerability of laser-assisted 5-FU delivery are warranted to clarify this issue. Moreover, it is also relevant to state that laser-assisted drug delivery was successful in both cases, but it is not possible to determine which treatment, either laser therapy or 5-FU, played the major role in terms of response.

Compared with older drug delivery techniques, such as dermabrasion, ablative fractional laser-assisted drug delivery produces more predictable results because only a fraction of the skin surface is ablated, with reduced recovery time. In addition, the possibility of modulating the laser parameters according to patient-specific skin characteristics minimizes the risk of adverse effects and improves treatment adherence.

References

1. Haedersdal M, Eriendsson AM, Paasch U, Anderson RR. Translational medicine in the field of ablative fractional laser (AFXL)-assisted drug delivery: a critical review from basics to current clinical status. *J Am Acad Dermatol* 2016;74:981–1004.
2. Nguyen BT, Gan SD, Konnikov N, Liang CA. Treatment of superficial basal cell carcinoma and squamous cell carcinoma in situ on the trunk

and extremities with ablative fractional laser-assisted delivery of topical fluorouracil. *J Am Acad Dermatol* 2015;72:558–60.

3. Glenn CJ, Parlette EC, Mitchell C. Fractionated CO₂ laser-assisted delivery of topical 5-fluorouracil as a useful modality for treating field cutaneous squamous cell carcinomas. *Dermatol Surg* 2015;41:1339–42.
4. Wenande E, Olesen UH, Nielsen MMB, Janfelt C, et al. Fractional laser-assisted topical delivery leads to enhanced, accelerated and deeper cutaneous 5-fluorouracil uptake. *Expert Opin Drug Deliv* 2017;14:307–17.
5. Banzhaf CA, Wind BS, Mogensen M, Meesters AA, et al. Spatiotemporal closure of fractional laser-ablated channels imaged by optical coherence tomography and reflectance confocal microscopy. *Lasers Surg Med* 2016;48:157–65.

CÉLIA L. PETERSEN VITELLO KALIL, MD
Universidade Federal do Rio Grande do Sul
Porto Alegre, Brazil

CLARISSA P. HERMAN REINEHR, MD
Department of Dermatology
Hospital de Clínicas de Porto Alegre
Universidade Federal do Rio Grande do Sul
Porto Alegre, Brazil

LAURA DE MATTOS MILMAN, MD
Private Clinic

RENATO M. BAKOS, MD, PhD
Department of Dermatology
Hospital de Clínicas de Porto Alegre
Universidade Federal do Rio Grande do Sul
Porto Alegre, Brazil

The authors have indicated no significant interest with commercial supporters.

EFFICACY AND PATIENT SATISFACTION OF A NEW NON ABLATIVE FRACTIONAL Nd:YAP LASER 1340 NM FOR FACIAL REJUVENATION IN BRAZILIAN PATIENTS.

Valeria Campos, MD. Juliana Jordão, MD. **Clinica Valeria Campos.** Jundiai - São Paulo, SP. Brazil.
original poster presented at ASLMS ANNUAL CONFERENCE 2011

SUMMARY: This present study wants to demonstrate a new fractional nonablative Nd:YAP 1340 nm laser technology that has been safely and effectively applied to treat photodamage in different skin types. Efforts to attend a growing demand of patients who seeks a procedure that treats wrinkles and improves skin textures with minimal to none downtime has been led to a constant upgrade in nonablative fractional lasers technologies. Intend of study is to determine the safety, efficacy and patient satisfaction of a new nonablative fractional Nd:YAP laser 1340 nm in facial skin rejuvenation of Brazilian skin types.

A comparison was made between treatments with low fluence and multiple passes versus treatments with higher fluence in a single pass. Twenty subjects with visible cutaneous photodamage, all with skin phototypes II to VI, were treated with a new fractional nonablative laser handpiece (ETHEREA® 1340 ProDeep®; INDUSTRA® Technologies, São Carlos, Brazil). All patients returned every 4 weeks for a total of 3 sessions and were followed up with monthly photos and grading until 6 months after their last treatment session. They also were asked to fill out a "Severity Scale" where levels of pigmentation, rhytides, skin tone and tightness, texture, and patient satisfaction were noted after last treatment session. Pigmentation, rhytides, skin tone and tightness, and texture were also evaluated by two physicians not involved in the study and by Canfield® VISIA® Complexion. All patients answered a questionnaire at the end of evaluation. Post-evaluation questionnaire showed that 100% of the patients felt improvement and 75% would recommend the same treatment to a friend.

A new fractional nonablative Nd:YAP 1340 nm laser can be safely and effectively performed to treat photodamage in darker skin types. Although most patients preferred the single pass laser treatment, we did not observe significant difference in the outcome after a low fluence multiple pass versus high fluence single pass treatment and the incidence of side effects were higher in the high fluence single pass treatment.

Further studies with a larger number of subjects and biopsy specimens for histological assessment are required.

BACKGROUND AND OBJECTIVES: Efforts to attend a growing demand of patients who seeks a procedure that treats wrinkles and improves skin textures with minimal to none downtime has been led to a constant upgrade in nonablative fractional lasers technologies. This present study wants to demonstrate a new fractional nonablative Nd:YAP 1340 nm laser technology that has been safely and effectively applied to treat photodamage in different skin types. Intend of study is to determine the safety, efficacy and patient satisfaction of a new nonablative fractional Nd:YAP laser 1340 nm in facial skin rejuvenation of Brazilian skin types by comparing treatments with low fluence and multiple passes versus treatments with higher fluence in a single pass.

STUDY DESIGN AND METHODS: Twenty subjects with visible cutaneous photodamage, all with skin phototypes II to VI, were treated with a new fractional nonablative laser handpiece (ETHEREA® 1340 ProDeep®; INDUSTRA® Technologies, São Carlos, Brazil). A comparison was made between treatments with low fluence and multiple passes versus treatments with higher fluence in a single pass, in two halves of the face. Parameters and treatment guidelines are shown in Table 1: Parameters and Treatment Guidelines.

All patients returned every 4 weeks for a total of 3 sessions and were followed up with monthly photos and grading until 6 months after their last treatment session. They also were asked to fill out a "Severity Scale" where levels of pigmentation, rhytides, skin tone and tightness, texture, and patient satisfaction were noted after last treatment session. Pigmentation, rhytides, skin tone and tightness, and texture were also evaluated by two physicians not involved in the study and by Canfield® VISIA® Complexion.

TABLE 1: Parameters and Treatment Guidelines

	RIGHT SIDE
number of passes	single
energy	120-140 mJ/mtz
total density • mtz	100 mtz/cm ²
spot size	Ø8 mm
	LEFT SIDE
number of passes	triple
energy	80-110 mJ/mtz
total density • mtz	100 mtz/cm ²
spot size	Ø8 mm

TABLE 2: Improvement Percentage

IMPROVEMENT PERC	SCORE VALUES
> 25%	poor
25-50%	good
51-75%	very good
< 75%	excellent

RESULTS AND CONCLUSION: Blinded observers of standardized photos taken before and after last treatment session has scored a percentage improvement, as shown on Table 2: Improvement Percentage. A final comparison between improvement with single or multiple passes treatments are shown in Figure 2: Single Pass and Multiple Pass Treatment Comparison

All patients answered a questionnaire at the end of evaluation and results are shown in Figure 1: Patient Treatment Evaluation. Post-evaluation questionnaire has shown that 100% of the patients felt improvement and 75% would recommend the same treatment to a friend. None difference between the two halves of the face has been noted, however 70% preferred a single pass laser treatment even using higher

energy by justifying a less painful treatment. The only noticed side effect was a transient hiperpigmentation in 10% of cases (2 patients, both skin type IV). No permanent side effects or scarring were seen in any treated cases.

Although, most patients has preferred a single pass laser treatment, we did not observe any significant difference at the outcome results by comparing both single and multiple passes treatments. However, side effects were higher in treatments performed with a single pass due to the high energy dosis applied.

A new fractional nonablative laser Nd:YAP 1340 nm can be safely and effectively to treat photodamage in darker skin types. Further studies with a larger number of subjects and biopsy specimens for histological assessment are still required.

BEFORE AND AFTER PHOTOS

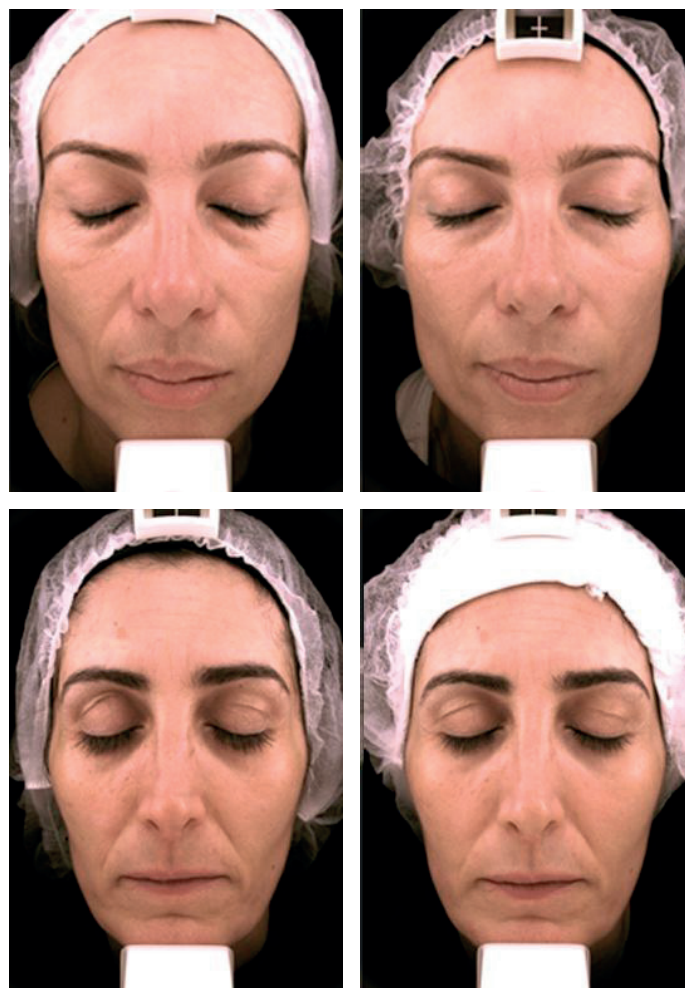

FIGURE 1: Patient Evaluation

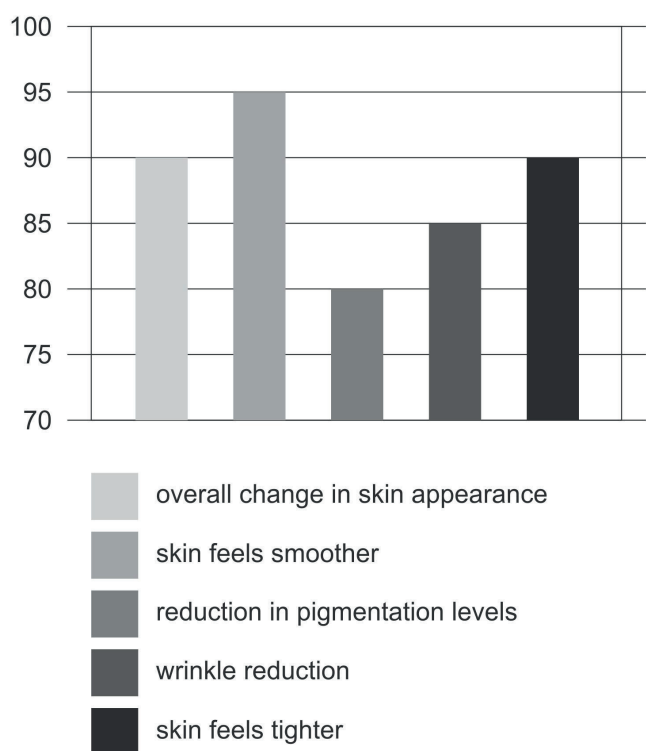
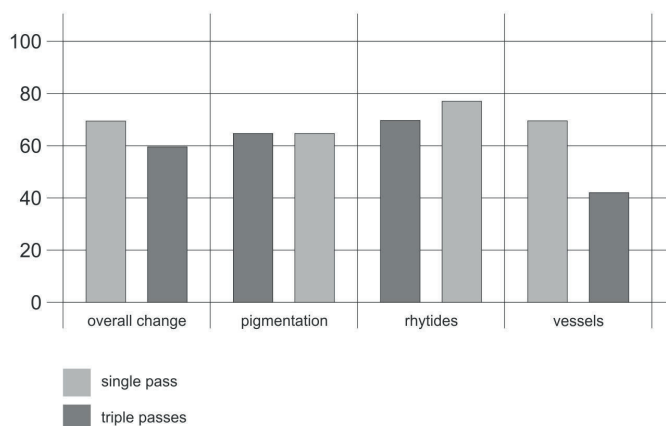


FIGURE 2: Treatment Comparison



Efficacy of Microneedling Versus Fractional Non-ablative Laser to Treat Striae Alba: A Randomized Study

Ana Paula Napolini, Juliana Catucci Boza, Vinicius Duval da Silva & Tania Ferreira Cestari

American Journal of Clinical Dermatology

ISSN 1175-0561

Am J Clin Dermatol
DOI 10.1007/s40257-018-0415-0



2018, Vol. 19, No. 1 (p. 1-10)
ISSN: 1175-0561 (Print); 1175-0562 (Online)

ONLINE FIRST

American Journal of Clinical Dermatology

Clinical Dermatology

Dermatitis
Diagnostic Criteria Used in Atopic Dermatitis Randomized Controlled Trials

Drug Reactions
Drug-Induced Pyoderma Gangrenosum

Genodermatoses
Birt-Hogg-Dubé Syndrome

Hair Disorders
Relationship between Alopecia Acreata and Viral Antigen Exposure

Immune System Disorders
Cutaneous Graft-Versus-Host Disease

Keratinization Disorders
Inherited Nonsyndromic Ichthyoses

Neoplasms
Cryotherapy for Anal High-Grade Squamous Intraepithelial Lesions in HIV-Positive Men who have Sex with Men

Psoriasis
Choosing First-Line Biologics for Moderate-to-Severe Psoriasis
Apremilast: A Novel Oral Treatment for Psoriasis and Psoriatic Arthritis

Rosacea
Diagnosis and Treatment of Rosacea Fulminans

Skin Barrier Repair
Natural Oils for Skin Barrier Repair

Adis

Your article is protected by copyright and all rights are held exclusively by Springer Nature Switzerland AG. This e-offprint is for personal use only and shall not be self-archived in electronic repositories. If you wish to self-archive your article, please use the accepted manuscript version for posting on your own website. You may further deposit the accepted manuscript version in any repository, provided it is only made publicly available 12 months after official publication or later and provided acknowledgement is given to the original source of publication and a link is inserted to the published article on Springer's website. The link must be accompanied by the following text: "The final publication is available at link.springer.com".



Efficacy of Microneedling Versus Fractional Non-ablative Laser to Treat Striae Alba: A Randomized Study

Ana Paula Naspolini¹ · Juliana Catucci Boza² · Vinicius Duval da Silva³ · Tania Ferreira Cestari¹

© Springer Nature Switzerland AG 2019

Abstract

Background Striae distensae (SD), an unsightly cutaneous condition characterized by epidermal atrophy, can affect the quality of life of women.

Objectives The aim of our study was to compare the efficacy of a neodymium:yttrium–aluminum–perovskite 1340 nm non-ablative fractional laser (NAFL) and the microneedling (MN) technique to treat striae alba (SA).

Materials and Methods NAFL and MN were used to treat striae on the longitudinally divided abdominal surface of 20 women classified as Fitzpatrick skin type III or IV (five sessions at monthly intervals). Photographs and skin biopsies were obtained during pretreatment and after the third and fifth treatment sessions for all patients. Patients and two independent evaluators assessed the clinical response using the Global Aesthetic Improvement Scale.

Results Patient-reported evaluation showed improvement of striae using both modalities, with no statistically significant difference between the groups. Collagen and elastic fibers were significantly increased ($p < 0.01$) after the third and fifth treatment sessions, with no significant difference between the modalities. In addition, Dermatology Life Quality Index scores showed significant improvement ($p < 0.001$) after the third and fifth treatment sessions compared with pretreatment values, with average values of 8.4 (standard error [SE] ± 1.21), 3.17 (SE ± 0.55), and 2.64 (SE ± 0.60), respectively. The mean pain score using the Visual Analog Scale in the MN group versus the NAFL group was 5.23 (SE ± 0.31) versus 2.39 (SE ± 0.22) [$p < 0.001$], and the mean duration of adverse events in the NAFL group versus the MN group was 4.03 days (SE ± 0.45) versus 3 days (SE ± 0.37) [$p = 0.02$].

Conclusion NAFL and MN are safe for treating SD, particularly in individuals classified as phototype III or IV. MN is a useful non-technology-dependent, low-cost alternative therapy for SA.

Clinical Trial Registration Number NCT03390439.

Key Points

No clinical trials are available aimed at investigating the effect of neodymium:yttrium–aluminum–perovskite (Nd-YAP) 1340 nm non-ablative fractional laser (NAFL) in the treatment of striae alba (SA), comparing its results with the effect of microneedling (MN).

Nd-YAP 1340 nm NAFL and MN 2.5 mm are similarly effective for the treatment of abdominal SA.

After Nd-YAP 1340 nm NAFL and MN 2.5 mm treatments, elastic and collagen fibers are increased in biopsies of SA, suggesting a demonstrable effect on dermal support.

Electronic supplementary material The online version of this article (<https://doi.org/10.1007/s40257-018-0415-0>) contains supplementary material, which is available to authorized users.

✉ Ana Paula Naspolini
paulanaspolini@gmail.com

¹ Universidade Federal do Rio Grande do Sul, Hospital de Clínicas de Porto Alegre, Porto Alegre, Brazil

² Hospital de Clínicas de Porto Alegre, Porto Alegre, Brazil

³ Barretos Cancer Hospital, Barretos, Brazil

1 Introduction

Striae distensae (SD) are a common cutaneous condition characterized by the loss/rupture of elastic fibers in the affected region. There are two forms of SD: striae rubra, characterized by erythematous and stretched lesions, and striae alba (SA), characterized by atrophic, wrinkled, and hypopigmented lesions [1]. Although frequently observed by patients and physicians, the prevalence of SD cited in the literature varies between 11 and 88% [2]. This unsightly skin condition can significantly affect a patient's psychosocial well-being and quality of life, particularly in women [3].

Despite several studies describing the topic, the exact pathophysiology of SD remains unclear [4]. A genetic predisposition to the occurrence of SD can be considered since there is a higher frequency in monozygotic twins [5]. A mechanical cause remains the most commonly accepted, being described in two conditions, i.e. in healthy skin that undergoes stretching and excessive distention, or in patients in whom the compromised dermis is subjected to normal mechanical loads [6]. Additionally, increased expression of estrogen, androgen, and glucocorticoid receptors, observed using histopathological analysis of skin from patients with SD, suggests that hormonal conditions may serve as an etiological contributor [7]. Furthermore, SD may be associated with the use of medications such as protease inhibitors (e.g. indinavir), in patients diagnosed with human immunodeficiency virus infection [8], and oral contraceptives [9].

SD are predominantly located on the buttocks, abdomen, hip, lumbosacral region, and breasts. Lesions situated on the arms and armpits are usually associated with changes in body weight [4] or muscle hypertrophy, whereas those over the abdomen and breasts are frequently related to gestation, becoming more evident after the 25th week of pregnancy [10].

Although several treatments have been proposed for SD, only one treatment strategy has shown consistent results [11]. Since 1999, the use of selective photothermolysis (SP) and fractional photothermolysis (FP) have been proposed as effective and safe therapies for SD, with low rates of adverse effects [12]. Manstein et al. first described the use of FP for SA in 2004 [13]; this modality, at a wavelength of 1540 nm, was recently approved by the US FDA to treat SA [14]. FP is based on the concept that thermal damage occurs in microscopic columns called thermal microzones (TMZ) that are surrounded by unheated tissue, which allows the keratinocytes of intact tissues to migrate into the injured areas and induce rapid healing [15]. Non-ablative lasers selectively penetrate the dermis, but protection of the epidermis is obtained by using

cooling during treatment. This improves their tolerability compared with ablative lasers. The erbium laser is also commonly reported in the treatment of SD for both the rubra and alba varieties [16].

Current trends favor the use of minimally invasive procedures, alone or in combination with other modalities, aimed at reducing the risk of complications and ensuring an earlier return-to-work for patients. Recently, microneedling (MN), or percutaneous collagen induction therapy, has been evaluated in clinical trials for the treatment of acne scars [17]. In studies with small patient samples, this technique has shown promising results in the management of SD [18, 19]. The MN method works on the principle of stimulating the production of collagen, without causing the complete de-epithelialization that is observed with the use of ablative techniques. MN has recently been applied in the treatment of SD, primarily because it causes few adverse effects, ensures rapid healing, and is a low-cost option.

This study aimed to evaluate and compare the clinical and histopathological response to the use of a non-ablative fractional laser (NAFL) versus MN in the treatment of abdominal SA.

2 Materials and Methods

2.1 Study Design

This was a 7-month, randomized, evaluator-blinded, intraindividual comparison (right versus left half of the abdomen, comparing the results between sessions) study (ClinicalTrials.gov identifier NCT03390439) conducted at the Hospital de Clínicas de Porto Alegre (HCPA), Brazil.

2.2 Subjects

Twenty women were selected through convenience sampling among the dermatology patients of HCPA. The main reason these women presented at the HCPA was consultation for striae. Inclusion criteria were women aged ≥ 18 years who presented with abdominal SA diagnosed after clinical examination, weight stability over 4 months prior to presentation, and being classified as Fitzpatrick phototype III or IV. Exclusion criteria were pregnant women, women who had given birth < 12 months prior to inclusion, a history of keloid scars, presenting with localized or systemic infection, immunosuppressed patients, use of photosensitizing medications, systemic corticosteroids or oral isotretinoin within 12 months prior to presentation, a history of collagen or elastic fiber diseases, infiltrative or topical anesthetic allergy, those who reported receiving treatment for striae during the last year prior to enrollment, and those with sun exposure during the study period.

2.3 Treatment

Each patient underwent simultaneous treatment with NAFL and MN applied to each section of the hemiabdomen (divided equally and longitudinally). Prior to the start of the study, each abdominal segment was randomized by the statistician using Microsoft Excel 2013 software (Microsoft Corporation, Redmond, WA, USA), using the 'rand' function, which generated a random number of 0 or 1, to receive one of the interventions. The principal investigator enrolled participants, assigning them to interventions according to the randomization results.

Treatment was performed five times at monthly intervals in all patients. Patients received local topical anesthesia with lidocaine 4% cream (Dermomax-Aché) under occlusion for 30 min, followed by cleansing with 2% aqueous chlorhexidine solution prior to the sessions.

The NAFL neodymium:yttrium–aluminum–perovskite (Nd:YAP) 1340 nm PRODEEP® (Etherea Platform; Vydenze Medical, São Carlos, Brazil) was used, according to the following settings: 90 MTZ/cm² tip, 90 mJ/TMZ, 2.5 Hz frequency, and one pass with 3 ms pulse duration, as specified by the manufacturer.

A Dr. Roller® (MTO Imports and Distribution Co., Sao Leopoldo, Brazil) 2.5 mm MN device was rolled over the corresponding segment of the hemiabdomen for a total of 10–15 passes in the same direction and at least four crossings to achieve a target therapeutic appearance (endpoint) of mild to severe erythema secondary to increased blood flow [20].

2.4 Clinical Evaluation

Photographs were obtained in the same environment and the camera was positioned on a flexible photographic tripod placed 30 cm from the abdomen, according to the height of each patient. The same sets were maintained at each time point: pretreatment and 1 month after the third and fifth treatment sessions, recording each hemiabdomen separately. Post-procedural pain was assessed after each session using the 0–10 range on the Visual Analog Scale (VAS) [21]. Adverse effects such as erythema, edema, crusting, blisters, dyschromia, and/or scars were evaluated at the visit subsequent to application of the treatment.

The validated Portuguese version of the Dermatology Life Quality Index (DLQI) was answered at pretreatment and after the third and fifth treatment sessions. This instrument comprises 10 questions, covering the following topics: symptoms, embarrassment, shopping and home care, clothes, social and leisure, sport, work or study, and close relationships. Each question refers to the impact of the skin disease on the patient's life over the previous week [22]. Two independent evaluators, blinded to the type of treatment,

used the Global Aesthetic Improvement Scale (GAIS) [23] to evaluate the photographic records. This scale is divided into five categories, which classify the response to treatment as 'very much improved', 'much improved', 'improved', 'no change', and 'worse'.

2.5 Histopathological Evaluation

Selected SA from each hemiabdominal segment underwent 3 mm punch biopsies at a distance of 0.5 cm away from the SA at the following time points: pretreatment and 1 month after the third and fifth sessions for all patients.

The specimens were fixed in 10% formalin and embedded in paraffin, followed by conventional processing techniques. The histopathological sections were stained using hematoxylin–eosin, orcein to highlight elastic fibers, and picosirius red to evaluate the density of the collagen fibers in the papillary and reticular dermis. Digital images were obtained in a random field from each of the slides (tiff format, 24-bit color, 2940 × 2940 pixels). The images were analyzed using ImagePro-Plus software, version 7.0 (Media Cybernetics, Silver Spring, MD, USA) and transformed into pixels to measure the proportion (percentage) of collagen and elastic fibers for the following time points: pretreatment and after the third and fifth treatments.

2.6 Statistical Analysis

Descriptive analyses were presented using percentages, means, and standard error (SE), and the weight stability and DLQI were evaluated using the Friedman test. Variations in the measurements of the epidermis at the different time intervals (pretreatment and after the third and fifth sessions) were assessed using delta calculations (difference between the baseline and the evaluation at a particular time point), followed by analysis of the generalized estimating equation (GEE).

Evaluation of intraprocedural pain, duration of adverse effects, the GAIS, and the percentage of collagen and elastic fibers were evaluated using the GEE analysis, according to the particular time points (treatment sessions) and the treatment groups (NAFL or MN). The Kappa coefficient was used to assess agreement among the clinical evaluators. Data were processed using SPSS version 18.0 software (SPSS Inc., Chicago, IL, USA) for statistical analysis, considering a significance level of 5%.

3 Results

Clinical and demographic data are presented in Table 1. No significant changes were observed in the weight of the women during visits ($p = 0.794$, Friedman test, data not

Table 1 Patient demographics ($n = 20$)

Characteristics	n (%)	Mean (\pm SD)
Age, years		35 (9.94)
Weight, kg		71.36 (16.08)
Body mass index		27.67 (6.03)
Fitzpatrick skin type		
III	10 (50)	
IV	10 (50)	
Smoking	0 (0)	
Striae distensae in other parts of the body	9 (45)	
Age of onset of the striae distensae, years		20.15 (4.99)
Related factors		
Pregnancy	16 (80)	
Weight gain	1 (5)	
Puberty	3 (15)	
Number of pregnancies		1.8 (1.10)
Average weight gain during pregnancy, kg (range)		16.1 (4–30)
Pregnancy < 25 years	15 (75)	
Family history of striae distensae	16 (80)	
Hormonal contraception	12 (60)	
Time of use, years		7.39 (7.81)

shown). During the study, three patients were excluded: one due to hypertrophic scarring at a biopsy site, and the remaining two patients withdrew from the study for personal reasons.

3.1 Patient-Reported Evaluation

Patient-reported clinical evaluation data are presented in Table 2. No patients reported any worsening of SA, and there was no significant difference between the MN and NAFL groups at the different time points of appraisal.

3.2 Clinical Evaluation Performed by Independent Evaluators

The evaluators had different opinions regarding the response of SA to the treatments. In the MN group, an improvement ('very much improved', 'much improved' or 'improved' on the GAIS scale) was observed in 44–50% of subjects after the third session and 75–88% after the fifth session. In the NAFL group, an improvement ('very much improved', 'much improved' or 'improved' on the GAIS scale) was observed in 44–55% of subjects after the third session and 75–94% after the fifth session (Fig. 1; Electronic Supplementary Figs. 1, 2).

There was no agreement between the two clinical evaluators with regard to the GAIS result after the pretreatment time point compared with after the third (Kappa = 0.011)

Table 2 Patients' evaluation after treatment of striae alba using the GAIS

	MN (%)	NAFL (%)	p value
After the third session			
1—Worse	0	0	0.528
2—No change	11	17	
3—Improved	58	35	
4—Much improved	29	41	
5—Very much improved	0	5	
After the fifth session			
1—Worse	0	0	
2—No change	6	6	
3—Improved	25	31	
4—Much improved	31	25	
5—Very much improved	37	37	

A p value ≤ 0.05 was considered statistically significant using analysis of the generalized estimating equation

GAIS Global Aesthetic Improvement Scale, MN microneedling, NAFL non-ablative fractional laser

and fifth sessions (Kappa = 0.135). With regard to the evaluation between treatments, there was agreement between the evaluators only in the MN-treated group after the second session (Kappa = 0.44, $p = 0.038$, GEE).

3.3 Quality-of-Life Assessment

The DLQI scores showed a statistically significant difference between the pretreatment time point and after the third and fifth sessions ($p < 0.001$, Friedman test) [Table 3]. No significant difference was observed between the third and fifth sessions ($p = 1$, Friedman test).

3.4 Thickness of the Epidermis

Calculation of the variation between the epidermal measurement (delta) was higher in the MN group than the NAFL group ($p = 0.014$, GEE) [Table 4, Fig. 2].

3.5 Quantification of Collagen and Elastic Fibers

The results of elastic fiber (orcein staining) and collagen fiber (picosirius red staining) quantification are presented in Figs. 3, 4 and 5. A significant increase in the amount of elastic and collagen fibers was observed between the three evaluated time points ($p < 0.01$, GEE). There was no statistically significant difference in the quantification of elastic and collagen fibers between the MN- and NAFL-treated groups ($p = 0.728$ and $p = 0.341$, respectively, GEE).

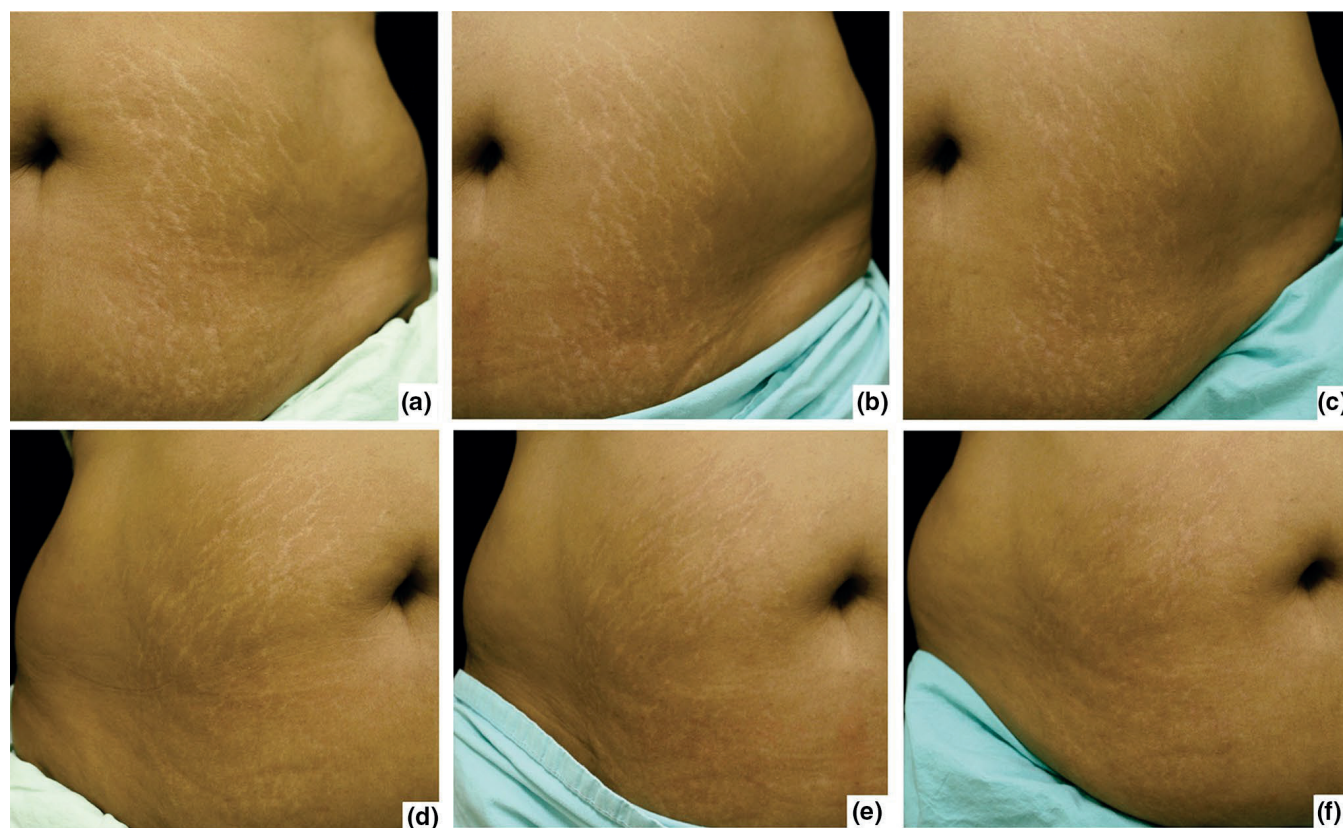


Fig. 1 Improvement of the striae after the third and fifth treatment sessions with MN and NAFL. Hemiabdomen treated with MN **a** pretreatment, **b** after the third treatment session, and **c** after the fifth

treatment session; and hemiabdomen treated with NAFL **d** pretreatment, **e** after the third treatment session, and **f** after the fifth treatment session. *MN* microneedling, *NAFL* non-ablative fractional laser

Table 3 Dermatology Life Quality Index

DLQI	Mean	SE	<i>p</i> value
Pretreatment	8.40	1.21	< 0.001
Third session	3.17	0.55	
Fifth session	2.64	0.60	

A *p* value ≤ 0.05 was considered statistically significant
DLQI Dermatology Life Quality Index, *SE* standard error

3.6 Evaluation of Pain During Procedures

The mean pain value on the VAS in the MN group versus the NAFL group was 5.23 (SE ± 0.31) versus 2.39 (SE ± 0.22). A significant difference in intraprocedural pain was noted between the MN and NAFL groups ($p < 0.001$, GEE) [Table 5]; however, there was no difference in pain between sessions ($p = 0.847$, GEE) [Electronic Supplementary Table 1].

Table 4 Thickness of the epidermis during the evaluation period (μm)

	Mean	SE	<i>p</i> value
Microneedling			
Pretreatment	73.57	4.36	0.014 ^a
Third session	89.6	4.12	
Fifth session	104.59	6.61	
Non-ablative fractional laser			
Pretreatment	86.18	7.5	
Third session	97.06	7.75	
Fifth session	99.04	5.96	

A *p* value ≤ 0.05 was considered statistically significant
SE standard error

^a*p* value for variation between the epidermal measurement using the delta calculation (difference between the baseline and the evaluation at a particular time point), followed by analysis of the generalized estimating equation

3.7 Evaluation of Adverse Effects

In the MN group, erythema was reported in 68.3% of the women, pruritus in 13.5%, and the absence of symptoms

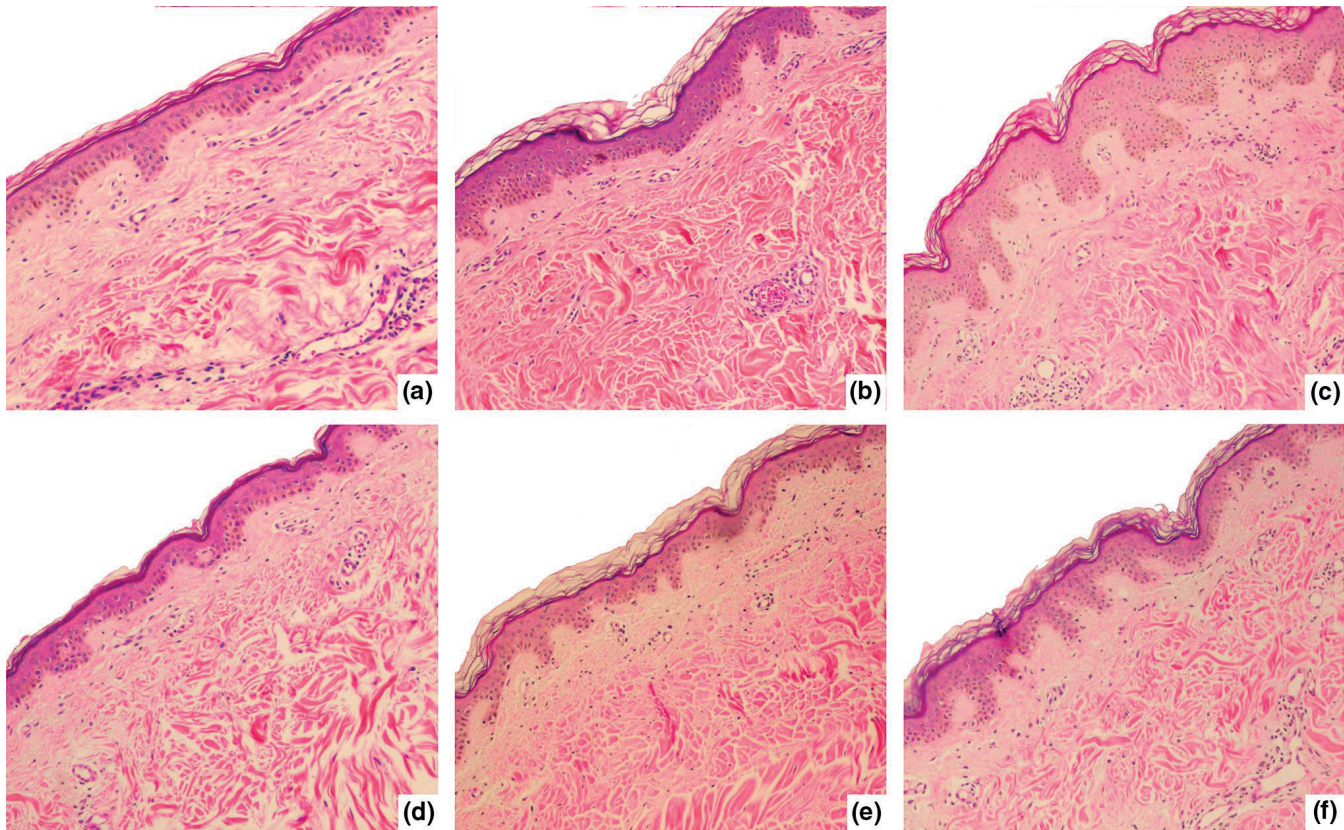


Fig. 2 Increased epidermal thickness after the third and fifth treatment sessions with MN and NAFL (hematoxylin-eosin, 10 ×). Hemi-abdomen treated with MN **a** pretreatment, **b** after the third treatment session, and **c** after the fifth treatment session; and hemi-abdomen

treated with NAFL **d** pretreatment, **e** after the third treatment session, and **f** after the fifth treatment session. *MN* microneedling, *NAFL* non-ablative fractional laser

post-procedure was reported in 7% of the women. In the NAFL group, erythema was reported in 66.3% of women, pruritus in 12.5%, presence of crusting in 1.9%, hyperpigmentation in 1%, and post-procedure pain was reported in 1.9% of women. The mean duration of adverse effects in the MN group versus the NAFL group was 3 days ($SE \pm 0.37$) versus 4.03 days ($SE \pm 0.45$). Adverse effects persisted longer in the NAFL group than in the MN group ($p = 0.02$, GEE) [Table 5].

In one woman, mild transient hyperpigmentation was noted on the NAFL side of the abdomen after the first treatment session, which was associated with non-follow-up care (e.g. sun protection and daily hydration with petrolatum cream). Hyperpigmentation showed a good response to 7 days of high-potency topical corticosteroid application and was not observed in subsequent sessions.

4 Discussion

A consistently effective therapeutic modality for the treatment of SD has been a challenge in dermatological practice. Although several treatments have been proposed, to date

there is no well-established and specific protocol available for the management of SA.

Among the women included in this study, 80% related the development of SA to a mean weight gain of 16.1 kg during gestation. Maia et al. reported the occurrence of striae in 50% of women who gained approximately 15 kg during pregnancy, and in 75% of women who gained > 15 kg [10].

In this study, we found a clinical and histopathological response for the treatment of abdominal SA with both NAFL Nd:YAP 1340 nm and MN. Although these are two distinct techniques, they may have similar penetration levels in the skin, depending on the energy applied to the laser and the size of the dermaroller needle. Sardana et al. evaluated the correlation between the depth and energy of NAFL 1550 nm (showing the closest resemblance to the laser used in this study). For each megajoule of energy applied, the depth of coagulation increased by approximately 10 μ m (10 mJ/100–150 mm; i.e. the application of a laser using 100 J would achieve coagulation of an area of 1 mm) [24]. Using the MN technique, the intensity of the elicited inflammatory reaction is proportional to the length of the needle used. It is estimated that a 3 mm needle penetrates only 1.5–2 mm of tissue (i.e. approximately 50–70% of its length)

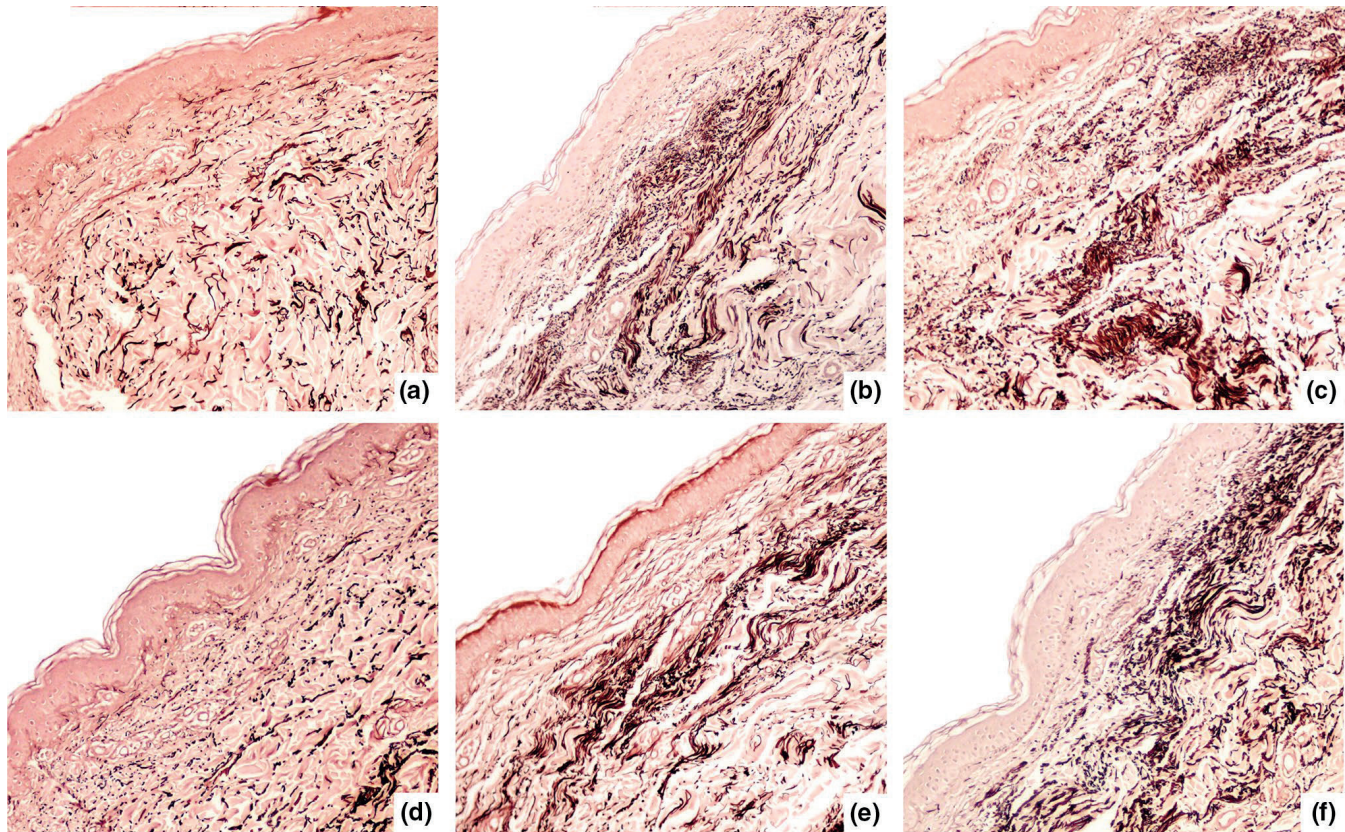


Fig. 3 Increased elastic fibers after the third and fifth treatment sessions with MN and NAFL (orcein stain, 10 ×). Hemiabdomen treated with MN **a** pretreatment, **b** after the third treatment session, and **c** after the fifth treatment session; and hemiabdomen treated with

NAFL **d** pretreatment, **e** after the third treatment session, and **f** after the fifth treatment session. *MN* microneedling, *NAFL* non-ablative fractional laser

[20]. Lima et al. evaluated the histopathological damage related to the needle length used for MN (0.5–2.5 mm). Microscopic examination immediately after application of the technique revealed predominantly vascular ectasia with extravasation of red blood cells. This finding was observed superficially, affecting the papillary dermis following the use of a 0.5 mm needle, and extended to the reticular dermis with the use of the longest needles. Optical microscopy revealed an intact epidermis, except for the presence of the needle passage site [20].

According to the opinions of patients and evaluators, there was improvement in the appearance of the SA with both treatments in this study. Similar results were demonstrated by Park et al., who showed excellent improvement in 43.8% of patients, with a high satisfaction index in 37.5% of individuals, without significant adverse effects after 3 monthly sessions of MN 1.5 mm [18]. The results shown in the present study agree with Yang and Lee [14], who found some degree of improvement in SA in 90.9% of subjects treated with three NAFL 1550 nm sessions.

Despite the patient-reported response to the treatments using the GAIS, there was no agreement between the

evaluators regarding the analysis of photographs. This difference of opinion may have occurred because the GAIS comprises five classification items, and disagreement between the evaluators could be expected if the degree of improvement was rated differently (very much improved versus much improved versus improved). This difficulty in the clinical evaluation of SD has also been reported by de Angelis et al., who described the lack of a standardized scale for the evaluation of SD and the establishment of a universal protocol for their treatment [16]. SA are hard to photograph in spite of the careful standardization of parameters. This difficulty may also have led to the lack of consensus between the evaluators. Guida et al. appraised the role of NAFL in the treatment of SA in 10 patients over 6 month sessions. In their study, clinical photographs and confocal microscopy were performed 1 month and 6 months after the last laser session. The authors reported that the response assessed by the patient-reported GAIS, and using confocal microscopy, could not be demonstrated in two-dimensional (2D) clinical photographs because they did not show the depth dimension of lesions [25]. Bertin et al. compared three-dimensional (3D) images of striae with histopathological analyses, and

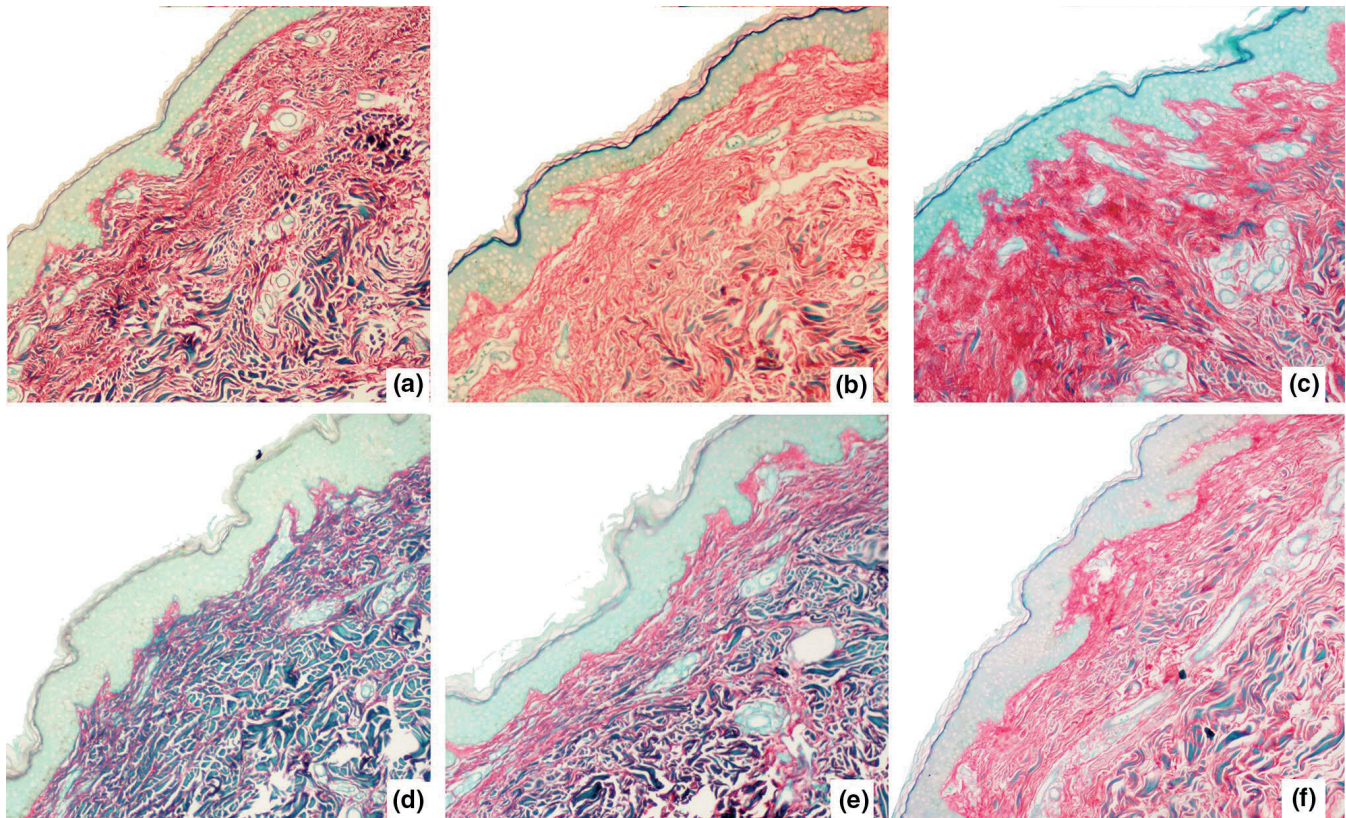


Fig. 4 Increased collagen fibers after the third and fifth treatment sessions with MN and NAFL (picrosirius red stain, 10 ×). Hemiabdomen treated with MN **a** pretreatment, **b** after the third treatment session, and **c** after the fifth treatment session; and hemiabdomen treated

with NAFL **d** pretreatment, **e** after the third treatment session, and **f** after the fifth treatment session. *MN* microneedling, *NAFL* non-ablative fractional laser

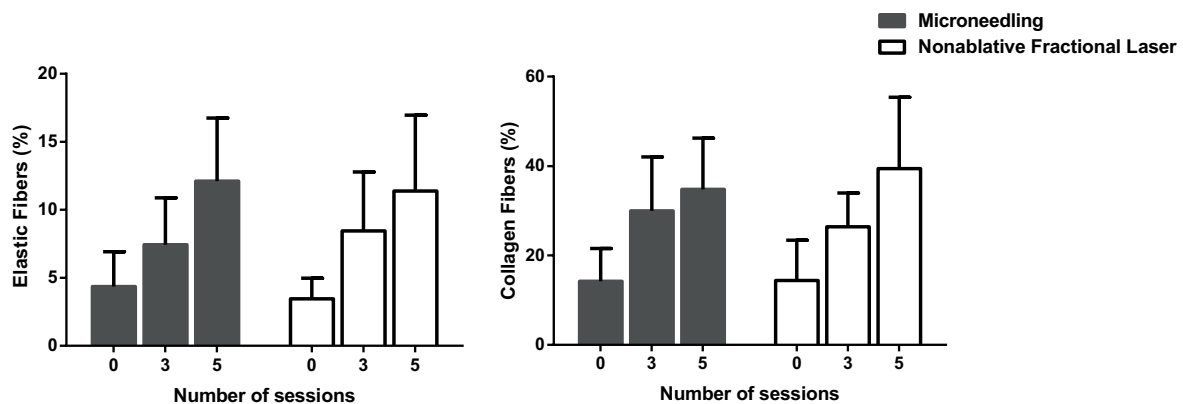


Fig. 5 Increased elastic and collagen fibers after the third and fifth treatment sessions with microneedling and non-ablative fractional laser

described the limitations of normal illumination with respect to 2D photographs of SA, highlighting the role of orthogonal polarized illumination to accurately record 2D streaks [26]. Despite this limitation, in this study, the patient-reported evaluation of response to treatment, as well as the improvement in quality of life, were in agreement with the noted histopathological changes.

Limited data are available in the literature regarding the effect of SD on the quality of life of women, with most studies only evaluating striae gravidarum. We noted a statistically significant reduction in the DLQI score after the third and fifth treatment sessions. Yamaguchi et al. appraised the effect of striae gravidarum in primiparous and multiparous pregnant women using the Skindex-29 score [27]. Pregnant

Table 5 Pain during application of the procedure and duration of adverse effects^a

	Pain (visual analog scale)			Duration of adverse effects (days)		
	Mean	SE	<i>p</i> value	Mean	SE	<i>p</i> value
Microneedling	5.23	0.31	< 0.001	3	0.37	0.02
Non-ablative fractional laser	2.39	0.22		4.03	0.45	

SE standard error

A *p* value ≤0.05 was considered statistically significant

^aData were evaluated using analysis of the generalized estimating equation

women with significant striae gravidarum presented a significantly higher score on the Skindex-29 when compared with those presenting with absent or mild striae gravidarum [28].

Histopathologically, an increase in elastic and collagen fiber quantification in the epidermal thickness was observed after the third and fifth sessions in the NAFL and MN groups, although a statistically significant increase was noted only in the latter. Few studies in the literature have quantitatively assessed the histopathology of SD after NAFL or MN treatment. Most studies have included small sample sizes in which epidermal thickness and collagen and elastic fiber analyses were evaluated in only a portion of the total sample, or assessment had been merely restricted to qualitative analysis of the data. Yang and Lee demonstrated an increase in epidermal thickness in the skin biopsies obtained in 3 of 20 patients treated using the NAFL 1540 nm and CO₂ laser in each hemiabdominal segment after three sessions at monthly intervals; however, no statistical analysis of this data was performed [14]. Kim et al. observed a statistically significant increase in epidermal thickness and quantification of elastic and collagen fibers 8 weeks after one NAFL 1550 nm application in six patients [29]. Regarding studies that used the MN technique, Zeitter et al. experimentally evaluated its effect in 30 rats divided into three treatment groups based on the following protocols: one dermaroller 1 mm session, four dermaroller 1 mm sessions, and four dermaroller 1 mm sessions followed by topical treatment using vitamin A, which showed a direct correlation between the epidermal thickness and the number of MN sessions performed [30]. Park et al. evaluated the response to treatment of SA and rubra using a dermaroller with needles 1.5 mm in length applied monthly for 4 months. Histopathologically, epidermal thickening and an increase in dermal collagen and elastic fibers were observed, although quantitative and statistical analyses of these results were not performed [18]. The only study using MN reported in the literature quantitatively evaluated the collagen and elastic fibers after six biweekly sessions using a dermaroller with needles 1.5 mm in length for the treatment of acne scars. El-Domyati et al. observed an increase in collagen fibers 3 months prior to the end of the study period. In contrast to the findings of our

study, no significant difference in collagen fibers was noted in the biopsies performed 1 month after treatment, as well as in the elastic fibers observed 1 month and 3 months after treatment [31].

Pain during application of the procedure was statistically higher in the MN-treated group in our study. It is known that pain, as well as downtime, is related to the depth of penetration of the needle, and general anesthesia is recommended for needles longer than 3 mm [32]. Dogra et al. evaluated the use of a dermaroller with needles 1.5 mm in length for the treatment of acne scars in 36 patients. After 1.5 h of topical anesthesia with lidocaine and prilocaine, pain was reported as the most common immediate symptom, and one patient required nerve block anesthesia to tolerate continuation of treatment [33].

Adverse events were observed to persist for a longer duration in the NAFL group, a finding that was in agreement with that reported by Cachafeiro et al., who compared the NAFL Er:YAG 1340 nm, a laser of the same wavelength and the same manufacturer as the one used in the present study, with a dermaroller with needles measuring 1.5 mm in length in the treatment of acne scars, showing a longer persistence of adverse effects in the NAFL-treated group [17].

5 Conclusions

The present study demonstrates the safety of NAFL and MN in the treatment of SA, with no significant differences observed between the treatment modalities based on patient-reported evaluation and in terms of the quantification of collagen and elastic fibers. Notably, despite the need for more effective topical analgesia in the MN group, the low rate of adverse effects associated with the therapies, particularly in patients classified as Fitzpatrick phototype III or IV, needs to be highlighted.

This evaluator-blinded, randomized clinical trial shows that NAFL and MN are comparable and effective in the treatment of SA. Participants in this study perceived clinical improvement from both treatments, confirming our impression and the statistical analysis of this parameter. Neither

treatment significantly affected patients' daily activities; however, MN showed a shorter duration of adverse effects compared with NAFL. In this way, MN could be viewed as a non-technology-dependent, low-cost alternative for the treatment of SA.

Finally, this evaluator-blinded, randomized clinical trial demonstrated that both NAFL and MN are comparable, effective, and well tolerated methods for treating SA. Clinical trials with larger sample sizes and using standard non-invasive methods for the clinical evaluation of lesions are clearly necessary to establish a reproducible and effective protocol for the treatment of striae.

Acknowledgements Evaluation assistance was provided by Clarissa Prieto Herman Reinehr, MD, Master in Medical Sciences, and Juliano Peruzzo, MD, Master in Medical Sciences.

Compliance with Ethical Standards

Conflicts of interest Ana Paula Napolini, Juliana Catucci Boza, Vinicius Duval da Silva, and Tania Ferreira Cestari have no conflicts of interest to declare.

Funding The research for this paper was financially supported by the Research and Events Incentive Fund (FIPE), HCPA, Brazil. In addition, this study received financial support from Aché Laboratory (Guarulhos, Brazil), Dr. Roller, MTO Importadora e Distribuidora (São Leopoldo, Brazil), and Vyence Medical Company (São Carlos, Brazil), who provided the anesthetics and devices used in this study.

Research involving human participants and/or animals This study was performed in accordance with the ethical standards of the Declaration of Helsinki, and was approved by the Ethics Committee of the Clinical Hospital of Porto Alegre (CAAE: 47639415.1.0000.5327).

Informed consent All patients were provided complete information regarding the procedures, and subsequently signed informed consent forms.

References

- Ross NA, Ho D, Fisher J, Mamalis A, Heilman E, Saedi N, et al. Striae distensae: preventative and therapeutic modalities to improve aesthetic appearance. *Dermatol Surg*. 2017;43(5):635–48.
- Al-Himdani S, Ud-Din S, Gilmore S, Bayat A. Striaedistensae: a comprehensive review and evidence-based evaluation of prophylaxis and treatment. *Br J Dermatol*. 2014;170(3):527–47.
- Tyler KH, Zirwas MJ. Pregnancy and dermatologic therapy. *J Am Acad Dermatol*. 2013;68(4):663–71.
- Soltanipoor F, Delaram M, Taavoni S, Haghani H. The effect of olive oil on prevention of striae gravidarum: a randomized controlled clinical trial. *Complement Ther Med*. 2012;20(5):263–6.
- Di Lerna V, Bonci A, Cattania M, Bisighini G. Striae distensae (rubrae) in monozygotic twins. *Pediatr Dermatol*. 2001;18(3):261–2.
- Gilmore SJ, Vaughan BL, Madzvamuse A, Maini PK. A mechanochemical model of striae distensae. *Math Biosci*. 2012;240(2):141–7.
- Cordeiro RCT, Moraes AM. Striae distensae: fisiopatologia. *Surg Cosmet Dermatol*. 2009;1(3):137–40.
- Darvay A, Acland K, Lynn W, Russell-Jones R. Striae formation in two HIV-positive persons receiving protease inhibitors. *J Am Acad Dermatol*. 1999;41(3 Pt 1):467–9.
- Har-Shai Y, Barak A, Taran A, Weissman A. Striae distensae of augmented breasts after oral contraceptive therapy. *Ann Plast Surg*. 1999;42(2):193–5.
- Maia M, Marçon CR, Rodrigues SB, Aoki T. Striae distensae in pregnancy: risk factors in primiparous women. *An Bras Dermatol*. 2009;84(6):599–605.
- Crocco EI, Mantovani PA, Volpini BM. Em busca dos tratamentos para Striae rubra e Striae Alba: o desafio do dermatologista. *Surg Cosmet Dermatol*. 2012;4(4):332–7.
- McDaniel DH. Laser therapy of stretch marks. *Dermatol Clin*. 2002;20(1):67–76.
- Manstein D, Herron GS, Sink RK, Tanner H, Anderson RR. Fractional photothermolysis : a new concept for cutaneous remodeling using microscopic patterns of thermal injury. *Lasers Surg Med*. 2004;34(5):426–38.
- Yang YJ, Lee GY. Treatment of striae distensae with nonablative fractional laser versus ablative CO₂ fractional laser: a randomized controlled trial. *Ann Dermatol*. 2011;23(4):481–9.
- Geronemus RG. Fractional photothermolysis: current and future applications. *Lasers Surg Med*. 2006;38(3):169–76.
- de Angelis F, Kolesnikova L, Renato F, Liguori G. Fractional nonablative 1540-nm laser treatment of striae distensae in Fitzpatrick skin types II to IV: clinical and histological results. *Aesthet Surg J*. 2011;31(4):411–9.
- Cachafeiro T, Escobar G, Maldonado G, Cestari T, Corleta O. Comparison of nonablative fractional erbium laser 1340 nm and microneedling for the treatment of atrophic acne scars: a randomized clinical trial. *Dermatol Surg*. 2016;42(2):232–41.
- Park KY, Kim HK, Kim SE, Kim BJ, Kim MN. Treatment of striae distensae using needling therapy: a pilot study. *Dermatol Surg*. 2012;38(11):1823–8.
- Mazzella C, Cantelli M, Nappa P, Annunziata MC, Delfino M, Fabbrocini G. Confocal microscopy can assess the efficacy of combined microneedling and skinbooster for striae rubrae. *J Cosmet Laser Ther*. 2018. <https://doi.org/10.1080/14764172.2018.1511913> (Epub 21 Aug 2018).
- Lima EV, Lima MA, Takano M, Takano D. Microagulhamento: estudo experimental e classificação da injúria provocada. *Surg Cosmet Dermatol*. 2013;5(2):110–4.
- Glass JS, Hardy CL, Meeks NM, Carroll BT. Acute pain management in dermatology: risk assessment and treatment. *J Am Acad Dermatol*. 2015;73(4):543–60.
- Martins GA, Arruda L, Mugnaini AS. Validação de questionários de avaliação da qualidade de vida em pacientes de psoríase. *An Bras Dermatol*. 2004;79(5):521–35.
- Hexsel D, Soirefmann M, Porto MD, Schilling-Souza J, Siega C, Dal'Forno T. Superficial dermabrasion versus topical tretinoin on early striae distensae: a randomized, pilot study. *Dermatol Surg*. 2014;40(5):537–44.
- Sardana K, Manjhi M, Garg VK, Sagar V. Which type of atrophic acne scar (ice-pick, boxcar, or rolling) responds to nonablative fractional laser therapy? *Dermatol Surg*. 2014;40(3):288–300.
- Guida S, Galimberti MG, Bencini M, Pellacani G, Bencini PL. Treatment of striae distensae with non-ablative fractional laser: clinical and in vivo microscopic documentation of treatment efficacy. *Lasers Med Sci*. 2018;33(1):75–8.
- Bertin C, Lopes-Dacunha A, Nkengne A, Roure R, Stamatatos GN. Striae distensae are characterized by distinct microstructural features as measured by non-invasive methods in vivo. *Ski Res Technol*. 2014;20(1):81–6.

27. Yamaguchi K, Suganuma N, Ohashi K. Quality of life evaluation in Japanese pregnant women with striae gravidarum: a cross-sectional study. *BMC Res Notes*. 2012;5:450.
28. Paula HR, Dini GM, Haddad A, Ferreira LM, Weiss MA. Tradução, adaptação cultural e validação do questionário de qualidade de vida norte-americano Skindex-29. *An Bras Dermatol*. 2014;89(4):600–7.
29. Kim BJ, Lee DH, Kim MN, Song KY, Cho WI, Lee CK, et al. Fractional photothermolysis for the treatment of striae distensae in Asian skin. *Am J Clin Dermatol*. 2008;9(1):33–7.
30. Zeitter S, Sikora Z, Jahn S, Stahl F, Strauß S, Lazaridis A, et al. Microneedling: matching the results of medical needling and repetitive treatments to maximize potential for skin regeneration. *Burns*. 2014;40(5):966–73.
31. El-Domyati M, Barakat M, Awad S, Medhat W, El-Fakahany H, Farag H. Microneedling therapy for atrophic acne scars an objective evaluation. *J Clin Aesthet Dermatol*. 2015;8(7):36–42.
32. Aust MC, Fernandes D, Kolokythas P, Kaplan HM, Vogt PM. Percutaneous collagen induction therapy: an alternative treatment for scars, wrinkles, and skin laxity. *Plast Reconstr Surg*. 2008;121(4):1421–9.
33. Dogra S, Yadav S, Sarangal R. Microneedling for acne scars in Asian skin type: an effective low cost treatment modality. *J Cosmet Dermatol*. 2014;13(3):180–7.

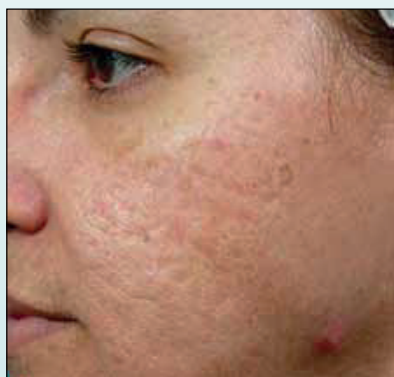ETHEREA's 1340 ProDeep LASER

Presents Effective Scar Management

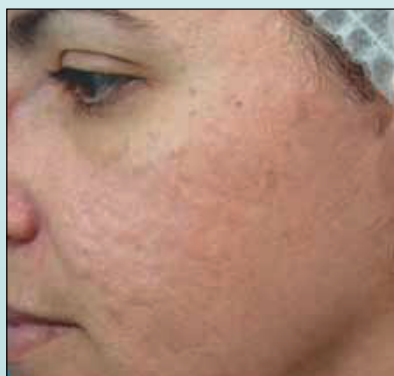

Carlos Roberto Antonio, M.D.
Dermatologic Surgeon
São José do Rio Preto, São Paulo, Brazil

"The 1340 ProDeep technology is capable of achieving truly remarkable cosmetic results, and I would highly recommend it to my colleagues."



Before Tx



After 1340 ProDeep Tx

Photos courtesy of INDUSTRA

By Ilya Petrou, M.D., Contributing Editor

As a global leader among laser and light-based technologies, the ETHEREA® platform from INDUSTRA® Technologies (São Carlos, São Paulo, Brazil) is widely considered the answer to a plethora of cosmetic indications including skin rejuvenation, hair removal, fractional skin resurfacing, photothermolysis, pigmented lesions, cutaneous vascular lesions of all depths, acne treatment and skin tightening. Equipped with five handpieces serving these varying indications, the 1340 ProDeep® handpiece is also proving to be a very safe and effective option for the treatment and management of scars.

Based on the time-tested, fractional, non-ablative Nd:YAP laser, the 1340 ProDeep handpiece has not only demonstrated great utility in the treatment of wrinkles and striae, but also improves the cosmesis of atrophic, surgical and acne scar lesions.

Carlos Roberto Antonio, M.D., a dermatologic surgeon in São José do Rio Preto, São Paulo, Brazil, has been using the 1340 ProDeep for about three years, almost ever since it was first launched by INDUSTRA. In his experience, "the handpiece is very effective not only in treatment of striae, but also in management of scars and has become my go-to laser for this indication. Indeed, I've never experienced a technology as efficacious as this one," he shared.

With a maximum power of up to 220 mJ/microscopic treatment zone (MTZ), the 1340 ProDeep laser emits a high dose of energy in fractional beams, which generate a higher intradermal heat that reaches the deeper subdermal layers of the skin, stimulating more profound collagen remodeling and subsequent neocollagenesis in the treated area. According to Dr. Antonio, this approach accelerates the recovery process, resulting in minimal to no downtime and improved treatment outcomes. Offering 3, 5 and 10 ms pulse sequences, in addition to fractional lenses of 100 and 400 MTZ, the 1340 ProDeep handpiece

provides a variety of treatment intensities, which Dr. Antonio feels is crucial for superior scar management.

"When working in deeper layers of the skin, one can achieve much more collagen tightening from laser energy due to the more effective penetration into the targeted tissue. In my opinion, the 1340 ProDeep handpiece technology provides a wide-range of treatment possibilities that achieve much better results compared to other similar devices on the market, which do not have the same reach or depth of action," Dr. Antonio stated. "I've already tried different technologies offered by many other devices, and I can tell you that 1340 ProDeep achieves the best results in scar management."

In contrast to other non-ablative laser devices currently available on the market, Dr. Antonio believes that the 1340 ProDeep handpiece can achieve faster cosmetic outcomes with a very high level of patient satisfaction. "It's a fact that the earlier treatment starts, the better the results that will be achieved," he said. By using more aggressive settings, the mean downtime following a scar treatment may range from two to three days max, during which patients experience a mild and transient erythema in the targeted area. Prior to the procedure, Dr. Antonio applies both topical anesthesia and cold-air cooling to enable the use of higher settings and help to ensure a high patient tolerability, improving treatment outcomes and the therapeutic response. When associating isotretinoin to the treatment sessions, patient satisfaction reaches about 95%.

"ETHEREA and the 1340 ProDeep handpiece offer me a unique treatment option that can substitute most office-performed surgeries due to its high efficacy in scar management," Dr. Antonio pointed out. "This technology is capable of achieving truly remarkable cosmetic results, and I would highly recommend it to my colleagues."

ETHEREA Provides Effective Treatment Solution for Leg Veins

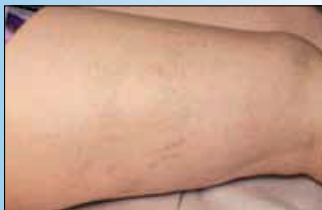

Luiz Marcelo Viarengo, M.D., Ph.D.
Vascular Surgeon
Jundiaí, São Paulo, Brazil

“This technology has demonstrated very effective treatment of different vascular lesions of diverse sizes and depths.”



Leg veins before Tx



Leg veins after 1064 nm LongPulse Nd:YAG Tx
Photos courtesy of Luiz Marcelo Viarengo, M.D., Ph.D.

By Ilya Petrou, M.D., Contributing Editor

ETHEREA® from INDUSTRA® (São Carlos, São Paulo, Brazil) is proving to be a very useful tool in aesthetic medicine, as it offers physicians the possibility of safely and effectively treating a plethora of aesthetic indications all from a single platform.

One of the major advantages that the ETHEREA system has over many of its competitors is its expandability of technologies, made possible by simply changing the various handpieces that come equipped with the device. This aesthetic treatment platform features five different, state-of-the-art technologies, one of which is the novel 1064 nm LongPulse® Nd:YAG laser, proven to be very effective in the treatment of vascular lesions of varying sizes.

Luiz Marcelo Viarengo, M.D., Ph.D., a vascular surgeon in Jundiaí, São Paulo, Brazil has had the opportunity to use ETHEREA and the 1064 nm LongPulse laser handpiece for more than six months. “This technology has demonstrated very effective treatment of different vascular lesions of diverse sizes and depths. I have often used the handpiece for the treatment of capillary hemangiomas, larger telangiectases and venulectasias in the legs, as well as telangiectatic matting or angiogenic flushing, non-cannulizable vessels and deep reticular veins less than 3 mm in diameter, achieving very positive treatment outcomes.”

In the treatment of vascular lesions in aesthetic medicine, there is a trend towards using longer wavelengths that penetrate deeper in the skin and better target deep lying vessels, while sparing the epidermis. Among the technologies currently available, the 1064 nm Nd:YAG LongPulse is viewed by many experts as one of the most effective and efficient options and is considered to be a gold standard technology for non-invasive treatment of superficial venous disease of the lower limbs.

Due to a high penetration depth through skin layers and its directed absorption by hemoglobin, the 1064 nm LongPulse can provide a constant and uniform distribution of energy over the treated area. In addition, longer pulse widths result in an extended heating of the targeted chromophores, which also increases vessel temperature and imminent constriction, involution and closure.

In Dr. Viarengo’s opinion, “ETHEREA has proven to be an outstanding device. For the treatment of vascular lesions in particular, the 1064 nm LongPulse handpiece appears to have mastered the perfect combination and relationship between optimal wavelength, energy density and pulse width, ensuring the best results for improved patient satisfaction.” Depending on the diameter of the targeted veins, Dr. Viarengo will often combine the 1064 nm LongPulse with other cosmetic vein treatments such as sclerotherapy (aethoxysclerol).

“First, I may inject a sclerosing agent in the target vessels that supply the blood to venous malformations, which results in an involution of those structures,” Dr. Viarengo began. “After the injection, I often follow-up with ETHEREA’s 1064 LongPulse and perform a few passes over the targeted lesion, as well as over the surrounding veins. This combination therapy can result in a more thorough and complete treatment of the vascular lesion.”

The 1064 nm LongPulse is a non-invasive technology offering efficacious treatment, with a few relative contraindications and no reported downtime. This technology offers safe procedures for all skin types without unwanted side effects. According to Dr. Viarengo, treatments with this device result in minimal to no discomfort and are very well tolerated by patients.

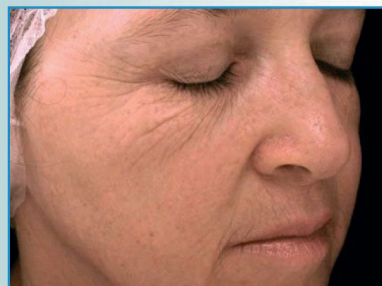Etherea Addresses Wide-Range of Aesthetic Treatment Indications

By Ilya Petrou, M.D., Contributing Editor

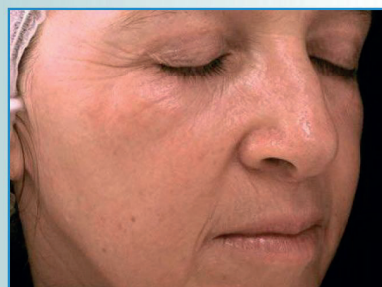

Valeria Campos, M.D.
Dermatologist
Jundiaí, Brazil

“Etherea is a very innovative expandable aesthetic treatment platform boasting state-of-the-art technologies that can be used for a plethora of cosmetic indications.”



Patient before Tx



Patient after Etherea Tx
Photos courtesy of Valeria Campos, M.D.

Stemming from the massive growth of the aesthetic medicine market is the need for state-of-the-art devices that can effectively address a plethora of aesthetic indications quickly, effectively and economically. INDUSTRA Technologies (São Carlos, São Paulo, Brazil) is meeting this challenge head-on with their Etherea system, which treats a broad range of cosmetic indications.

Etherea is an expandable, aesthetic treatment platform engineered to address a broad range of issues including hair removal, acne treatment, skin rejuvenation, fractional ablative and non-ablative skin resurfacing, pigmented lesions, vascular lesions, both face and leg veins, as well as skin laxity and skin tightening. This cleverly designed system implements the science of other, leading devices on the market, while improving upon established technologies by offering five advanced light and laser handpieces. Featured handpieces include IPL-Sq: the latest generation of intense pulsed light technology; the intenselR: a high-powered infrared light; the 1064 LongPulse: a long pulsed Nd:YAG laser; the 1340 ProDeep: a fractional Nd:YAP laser; and the 2940 DualMode: a fractional Er:YAG laser.

Combining the power of square-wave pulse technology found in the IPL-Sq handpiece, with the intenselR handpiece – a high-powered halogen lamp that filters both light absorption and reflection, allowing the energy to heat a specific tissue depth – results in more efficient, precise and safer treatments.

“Unlike traditional IPL systems, this technology releases energy through a controlled and microprocessed discharge to deliver uniform energy all along the pulse,” explained Valeria Campos, M.D., a dermatologist in Jundiaí, Brazil. “This ideal configuration helps to ensure higher safety and efficacy of clinical procedures, as well as improved aesthetic outcomes,” she added.

Considered a gold standard technology, the 1064 LongPulse laser provides non-invasive treatments of both deep and superficial veins, including those on the face and legs. Dr. Campos reinforced that Etherea’s Nd:YAG is one of the most requested technologies in modern aesthetic leg vein treatments, as it offers a perfect combination of wavelength, energy and pulse width.

Etherea’s platform also includes the 1340 ProDeep technology, a non-ablative, fractional laser indicated for the treatment of wrinkles, unwanted textural irregularities, striae, acne and surgical scars. Additionally, it is one of the most recommended technologies to treat melasma. “The 1340 ProDeep wavelength penetrates twice as deep as most non-ablative lasers on the market, achieving an improved treatment efficacy throughout the targeted skin layers,” Dr. Campos advised.

In recent years Er:YAG technology has evolved, and according to Dr. Campos, ablative fractional skin resurfacing can be best achieved today via Etherea’s 2940 DualMode technology. Combining both hot and cold Erbium fractional ablation and coagulation, this innovative technology increases residual thermal damage in the tissue, while stimulating neocollagenesis. The result is fewer complications and adverse events, improved safety, less downtime, as well as less pain to patients, compared to CO₂ laser technology.

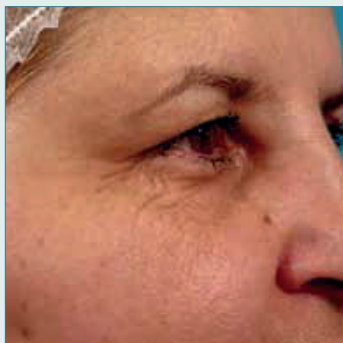
“Etherea is a very innovative, expandable aesthetic treatment platform boasting state-of-the-art technologies that can be used for a plethora of cosmetic indications,” said Dr. Campos. “I am convinced that these technologies will not only satisfy but also fascinate aesthetic physicians, as well as the most demanding aesthetic patients.”

ETHEREA Defines Versatility and Efficacy in Aesthetic Treatments

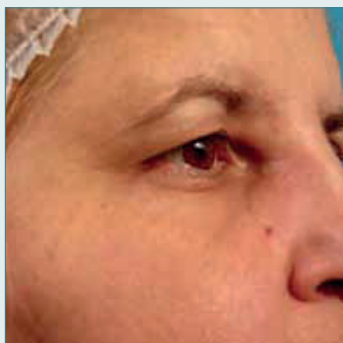


Juliana Jordão, M.D.
Dermatologist
Curitiba, PR, Brazil

“For moderate-to-severe wrinkles, combining the 1340 ProDeep and 2940 DualMode technologies in the same session brings quite improved results.”



Before Tx



After ETHEREA 2940 DualMode Tx
Photos courtesy of INDUSTRA

By Ilya Petrou, M.D., Contributing Editor

Since entering the aesthetic market, ETHEREA® from INDUSTRA Technologies (São Carlos, São Paulo, Brazil) has firmly established itself as a formidable competitor to other leading aesthetic devices, offering physicians and their patients safe and effective treatments for various indications, all from a single platform.

Emphasizing the versatility of this novel workstation, ETHEREA is an expandable platform powered by state-of-the-art technologies including IPL-Sq®, intensellR® and 1064 LongPulse® Nd:YAG laser and light technologies, as well as the innovative 1340 ProDeep® Nd:YAP and 2940 DualMode® Er:YAG fractional lasers. Each of these five handpieces can be selectively chosen to treat a variety of aesthetic indications including fine lines and wrinkles, textural irregularities, striae distensae, as well as acne and surgical scars.

According to Juliana Jordão, M.D., a dermatologist in private practice in Curitiba, PR, Brazil, “Patients are pleased with the results I achieve using ETHEREA’s handpieces. In my experience, patients will perceive a faster improvement of the indications addressed compared to some other treatment options.”

Though the non-ablative 1340 ProDeep and the ablative 2940 DualMode lasers can be used alone for fractional skin rejuvenation, combined treatments with these modalities can enhance and improve upon the outcomes achieved.

“For moderate-to-severe wrinkles, combining the 1340 ProDeep and 2940 DualMode technologies in the same session brings quite improved results, reminiscent of those achievable with CO₂ laser resurfacing, but with much less complications,” Dr. Jordão noted. “I first use the 1340 ProDeep in areas with deep wrinkles and follow-up with the 2940 DualMode for full-face treatment.”

While the 1340 ProDeep is an excellent choice for both new and old striae distensae lesions, distensible acne scars, surgical scars and mild-to-moderate wrinkles, Dr. Jordão feels that the 2940 DualMode is also a good treatment choice for mild-to-moderate wrinkles, distensible acne scars and dilated pores as well.

Dr. Jordão explained that the 2940 DualMode handpiece has three treatment options, namely, coagulative single mode, pure ablative single mode and DualMode®, which combines both coagulative and ablative pulses in a single shot. By using these parameter options, she said that many different skin conditions can be treated safely, including extra-facial rejuvenation, seborrheic keratosis and clear melanosis, indications that most IPL technologies are not able to treat.

“The 1340 ProDeep handpiece has a deeper level of action when compared to other non-ablative fractional laser systems currently available on the market,” Dr. Jordão stated. “As such, it is much more effective for atrophic scars, mild-to-moderate wrinkles and striae distensae than most other available devices.”

With a greater spot size, the IPL-Sq is well tolerated by patients, Dr. Jordão advised, owing to the ContactCooling system integrated within the sapphire tips, in addition to two parameter settings which help achieve a faster and painless treatment. The 1340 ProDeep treatment is also very well tolerated and equally painless, she continued, particularly when used together with INDUSTRA’s Siberian® cold-air cooling system.

“Patients are also very comfortable during the 2940 DualMode treatment sessions,” she added. “They may feel a burning sensation by the end of procedure, which is transient and typically persists for a just a few hours.”

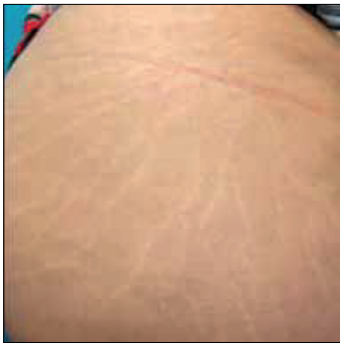ETHEREA's 1340 ProDeep Laser

Achieves More Effective Treatment of Striae Distensae

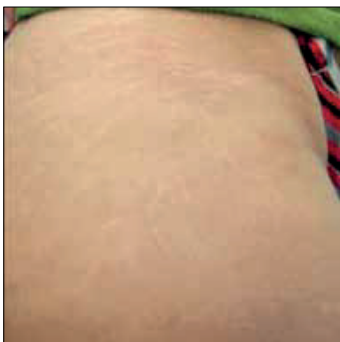

Valeria Campos, M.D.
Dermatologist
Clinica Valeria Campos
Jundiai, São Paulo, Brazil

"I am convinced that the state-of-the-art technologies in ETHEREA, such as the 1340 ProDeep will not only satisfy, but will certainly fascinate physicians in terms of quick and safe treatments, as well as the outcomes achieved."



Striae distensae before Tx



Striae distensae after ETHEREA ProDeep Tx
Photos courtesy of INDUSTRA

By Ilya Petrou, M.D., Contributing Editor

Among the many laser systems on the market today, INDUSTRA's (São Carlos, São Paulo, Brazil) ETHEREA® is considered by many experts as one of the most versatile devices currently available, offering safe and effective aesthetic treatment solutions for many indications.

Valeria Campos, M.D., a dermatologist at Clinica Valeria Campos in Jundiai, SP, Brazil, has no doubt that ETHEREA is one of the most reliable platform devices available on the market today. "This versatile workstation incorporates top-rated technologies that cater to the specific growing needs of both the aesthetic and medical markets, resulting in easier, faster and truly effective treatments," she said.

Powered by premium time-tested laser and light-based technologies such as IPL-Sq®, intenselR®, 1064 LongPulse® Nd:YAG, 2940 DualMode® fractional Er:YAG and 1340 ProDeep® fractional Nd:YAP, the expandable ETHEREA platform is a very effective, yet gentle workhorse that can address a plethora of indications, including fine lines and wrinkles, unwanted textural irregularities, post-surgical, atrophic and acne scars, striae distensae, hair removal, skin rejuvenation and tightening, fractional skin resurfacing, fractional photothermolysis, pigmented lesions, as well as superficial and deeper vascular lesions.

Already shown to be very effective in the improvement of mild wrinkles and scarring, the 1340 ProDeep fractional Nd:YAP laser is proving to be an excellent treatment option for striae distensae as well. Compared to other systems, Dr. Campos said that the 1340 ProDeep provides fractional non-ablative skin rejuvenation at a much greater depth and efficacy.

"INDUSTRA's unique ProDeep technology uses a revolutionary new wavelength that ensures a greater depth of

penetration of the laser energy into the subdermal layers, stimulating neocollagenesis in these deeper layers and resulting in a more effective option to treat striae," Dr. Campos reported. "The relationship between the applied energy density and the ProDeep technology increases the stimulation on deep collagen, providing a visible improvement in skin tonus and health as well."

ProDeep works by applying a high energy dose (up to 220 mJ) per microscopic treatment zone (mtz) in fractional beams, generating a higher intradermal heating, which increases the efficacy of treatment in terms of a deeper collagen remodeling and neocollagenesis in the targeted tissues. This approach will accelerate the recovery process resulting in minimal to no downtime and improved treatment outcomes. Offering 3, 5 and 10 ms shot sequences, as well as fractional lenses of 100 and 400 mtz, the 1340 ProDeep handpiece provides a wide-range of treatment intensities.

According to Dr. Campos, ETHEREA 1340 ProDeep offers the perfect relationship between energy density of fractional lenses, laser beam penetration and wavelength. The revolutionary technology provides a treatment option for striae that is equal to none, resulting in excellent outcomes achievable in fewer sessions, typically between three and five.

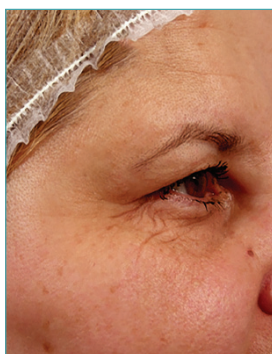"I am convinced that the state-of-the-art technologies in ETHEREA, such as the 1340 ProDeep will not only satisfy, but will certainly fascinate physicians in terms of quick and safe treatments, as well as the outcomes achieved. Furthermore, since this platform can be upgraded with new and evolving technologies, the device not only offers a complete treatment system, but a perfect solution to aesthetic marketing as well," Dr. Campos said.

ETHEREA's 2940 DualMode Laser Handpiece Rivals Established Competitors

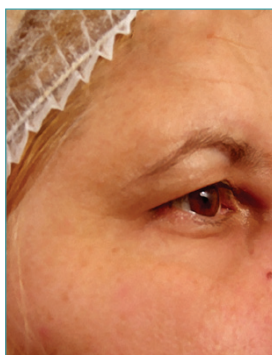

Alexandre Filippo, M.D.
Dermatologist
Rio de Janeiro, Brazil

"In contrast to other devices, the ETHEREA platform with the 2940 DualMode laser handpiece offers practitioners the perfect synergy between fluence, pulse width and frequency."



Before Tx



After Etherea 2940 DualMode Tx

By Ilya Petrou, M.D., Contributing Editor

According to Alexandre Filippo, M.D., a dermatologist in private practice in Rio de Janeiro, Brazil, ETHEREA's 2940 DualMode laser handpiece from INDUSTRA Technologies (São Carlos, São Paulo, Brazil) has proven to be very effective in skin rejuvenation treatments, achieving significant tightening, which results in excellent outcomes that rival other devices in its class.

The evolution and fine tuning of Er:YAG laser technology has resulted in state-of-the-art aesthetic devices that can treat a wide variety of indications. In Dr. Filippo's opinion, "modern fractional ablative skin resurfacing can be best achieved with 2940 DualMode technology, which proves to be ideal in the treatment and improvement of fine wrinkles, dyspigmentation, skin texture, acne and post-surgical scars, keratoses and verrucae, as well as the renewal of aging and photodamaged skin."

ETHEREA's 2940 DualMode handpiece represents a new generation of Er:YAG technology. This novel laser combines hot and cold erbium, producing double pulses that can achieve both fractional ablative and coagulative effects simultaneously. Dr. Filippo feels that this novel combination increases residual thermal damage (RTD) in the targeted tissues while directly stimulating fibroblasts, resulting in subsequent neocollagenesis.

For Dr. Filippo, "the results achieved with fractional ablative skin resurfacing treatments using the DualMode laser handpiece are truly remarkable. Compared to CO₂ laser technology, the innovative 2940 DualMode allows me to perform safer fractional skin resurfacing treatments with less pain, fewer complications and side effects, while keeping downtime to a minimum."

Dr. Filippo also noted that the 2940 DualMode handpiece is very reliable, particularly in regards to delivering controlled ablation and / or tissue coagulation. "This superior control results in safer procedures and improved efficacy in both skin tightening and surface laser peel treatments." Dr. Filippo often chooses this handpiece for patients seeking more aggressive treatments, without having to be concerned about the adverse events often experienced with other fractional ablative systems.

The DualMode handpiece offers three treatment modalities including an ablative pulse ranging from 300 to 500 μ s in width, a coagulative pulse (pulse width greater than 1 ms), and a DualMode with both ablative and coagulative pulses (first and second pulse, respectively), the latter of which provides more aggressive effects than any of the single pulse modes.

"In contrast to other devices, the ETHEREA platform with the 2940 DualMode laser handpiece offers practitioners the perfect synergy between fluence, pulse width and frequency," Dr. Filippo advised. "This synergy translates into unique treatment versatility, allowing me to effectively and efficiently address a range of aesthetic indications with excellent outcomes and responses."

Dr. Filippo determines the treatment protocol based on the patient's indications, goals and the penetration depth of the laser energy. "We usually improve outcomes and skin response by adding other technologies during the treatment session such as ETHEREA's 1340 ProDeep handpiece, MultiWaves or light-emitting diode therapy, to assist and expedite recovery post-procedure," he said.

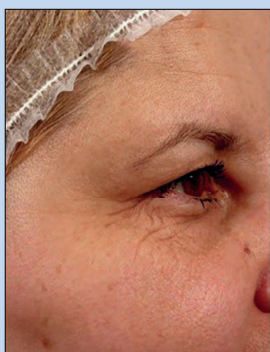Etherea's Expandable Platform Incorporates New Technology

By Ilya Petrou, M.D., Contributing Editor



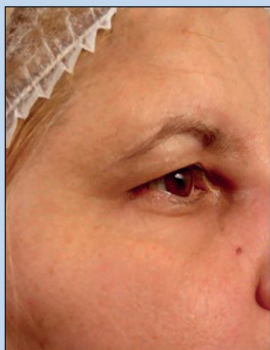Nuno Osório, M.D.
Dermatologist
São Paulo, Brazil

As an expandable platform, Etherea from INDUSTRA (São Carlos, São Paulo, Brazil) easily incorporates new laser and light technologies, allowing aesthetic physicians to safely and effectively perform a plethora of treatments from one device. This intelligently engineered system achieves significant results for some of the most common indications in aesthetic medicine today, including hair removal, skin rejuvenation, fractional ablative and non-ablative skin resurfacing and treatment of acne, pigmented lesions, vascular lesions, facial and leg veins, as well as skin laxity.



Before Tx

Currently equipped with five laser and light handpieces, including the IPL-Sq: the latest generation of intense pulsed light (IPL) technology, the intenselR: high-powered infrared (IR) light, the 1064 LongPulse: long-pulsed Nd:YAG laser, the 1340 ProDeep: fractional Nd:YAP laser and the 2940 DualMode: fractional Er:YAG laser, Etherea can be expanded even further to better facilitate many of the treatments performed in an aesthetic practice – safely, effectively and economically.



After Etherea 2940 DualMode Tx

For Nuno Osório, M.D., a dermatologist in São Paulo, Brazil, the state-of-the-art 2940 DualMode fractional Er:YAG laser is one of Etherea's stellar features, representing a new age in modern fractional ablative resurfacing. "DualMode technology for fractional Er:YAG laser skin resurfacing is extremely reliable and provides fully controlled ablation and coagulation levels in tissues, allowing me to use it in non-facial areas including the neck, chest and arms," he said. "This allows much more versatility to patients and practitioners."

This innovative DualMode technology combines both hot and cold erbium fractional ablation and coagulation, increasing residual thermal damage in the tissue while

directly stimulating neocollagenesis. This results in fewer complications and adverse effects, improved safety, shorter downtimes, as well as less pain to patients.

Dr. Osório often uses this technology in patients who demand and/or require more profound results. "Though treatments are more aggressive, the adverse effects and complications remain low, especially when compared to other fractional ablative systems currently available."

The treatment protocols and suggested guidelines used with the DualMode depend on treatment goals. According to Dr. Osório, cosmetic outcomes can be improved with the addition of Etherea's other technologies such as the 1340 ProDeep laser handpiece, MultiWaves, or light-emitting diode (LED) therapy recovery in maintenance treatments.

Etherea's 2940 DualMode handpiece offers three treatment modalities, namely an ablative pulse (with a pulse width from 300 μ s – 500 μ s), a coagulative pulse (with a pulse width greater than 1 ms), and the DualMode (with both ablative and coagulative pulses – first and second pulse, respectively). "A combination of pulses can achieve more aggressive cosmetic effects than any of the single pulse modes, which may prove to be very useful in patients requiring more skin rejuvenation work," Dr. Osório said.

In Dr. Osório's experience DualMode technology offers a perfect synergy between fluence, pulse width and frequency, highlighting the unique versatility that the Etherea platform brings to the market. "The 2940 DualMode handpiece alone has significantly increased the turnover in my daily practice and patient satisfaction. In my experience, Etherea's platform can address the most sought after cosmetic procedures, even in my most demanding patients."



Case Report:

Q-switched LASER to treat ochre dermatitis after venous disease therapy.

Carlos Eduardo de Freitas Jorge, vascular surgeon.
Belo Horizonte, MG, Brazil.

White paper case report described by vascular surgeon Carlos Eduardo de Freitas Jorge, from Belo Horizonte, Minas Gerais (MG), Brazil.

He uses the ETHEREA-MX® platform, combining different technologies:

- ▶ **LongPulse®**, for transdermal treatment of vascular lesions in the lower limbs;
- ▶ **ACROMA-QS®**, for cases of adverse events related to blood extravasation, as in the case of ochre dermatitis.

At first, after an evaluation is completed and the venous disease is confirmed, treatment is carried out. Next, the treatment using ACROMA-QS® tarts, eliminating the risk of incidence of other hemochromatosis. "I mark the skin to observe the tissue's reaction to the use of different parameters (shown in the photos)".

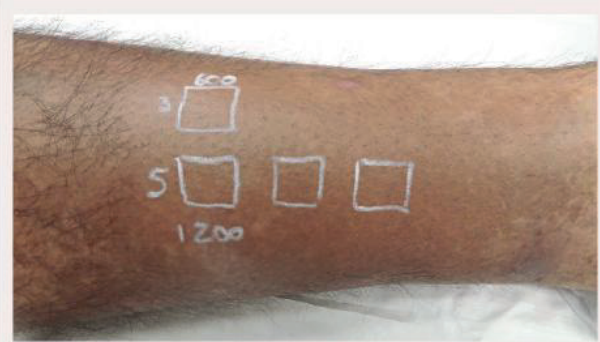


Image 1: pre-treatment evaluation.

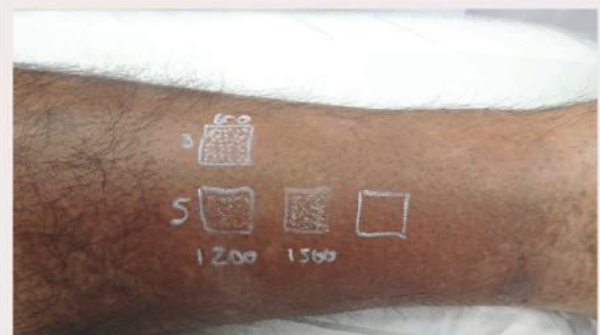

Image 2: Immediate reaction after using ACROMA-QS® LASER to treat ochre dermatitis.

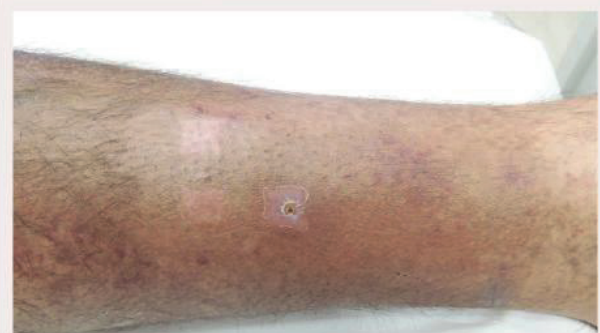

Image 3: 30 days after the treatment is completed. In this case, while the parameter with 1,500 mJ presents crusting in the post-treatment, a dose of 1,200 mJ shows satisfactory results. Around 8 sessions are recommended, with a 30 to 40-day interval between each session.

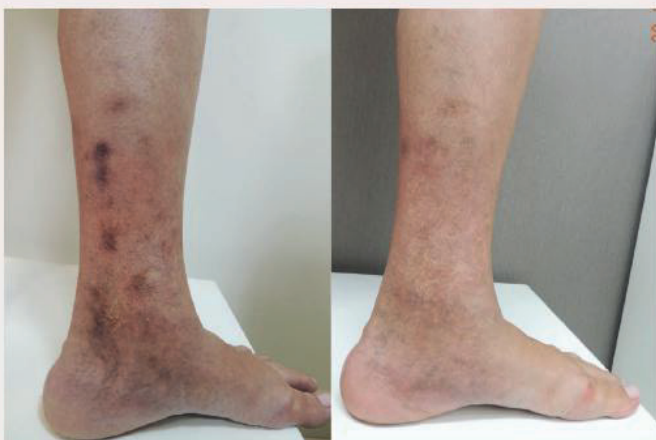

Photo before the treatment and after 8 sessions, using the recommended parameters – 3 or 5 mm spot, ranging from 600 to 1,500 mJ, starting with 5 mm at 1,200 mJ, and reaching up to 3 mm at 600 mJ.



Case Report:

Lightening eyebrow micropigmentation with Q-Switched LASER

Fátima Brito, dermatologist
Recife, PE, Brazil

This is a case report in the form of a white paper by Dr. Fátima Brito, dermatologist, from Recife, PE, Brazil. Dr. Fátima used the ETHEREA-MX® platform, with the ACROMA-QS® handpiece.

Treatment:

- ▶ Micropigmentation of the eyebrows has become an increasingly common procedure for adult women. However, in many cases, errors in performing the technique, or alteration of the initial pigment, have caused unaesthetic results.
- ▶ Removing the pigment is sometimes done by using acids, but the results are slow and often unsatisfactory. As described in literature, the removal method that has the highest rate of success is by Q-Switched LASER with high energy and short pulse time (nanoseconds).
- ▶ The ACROMA-QS® handpiece from ETHEREA-MX®, works with 20 ns and 1064-nm and 532-nm wavelengths, making it an efficient tool to reduce the amount of pigment color in both micropigmentation and conventional tattoos.
- ▶ The interaction of the LASER will cause photo mechanical disruption of the ink particles, breaking them into smaller fragments, making phagocytosis possible.
- ▶ **Parameters used:**
Spot size 5 mm, 1064 nm, 600 mJ to 1200 mJ increased gradually as the region became lighter. In this case, whose objective was to lighten the micropigmentation, 3 sessions were performed, with intervals of 30-45 days.

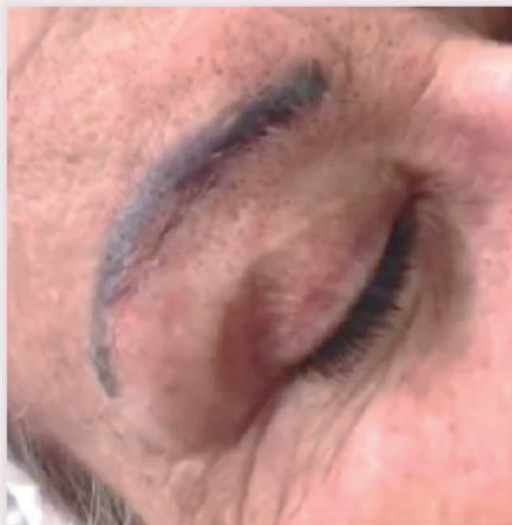

Image 1: Pre-treatment evaluation

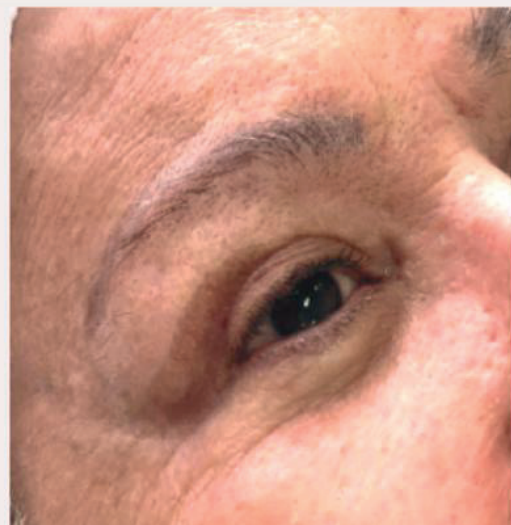

Image 2: Post treatment result



Case Report:

LASER q-switched 532 nm for the treatment of flat warts on face.

Guilherme Bueno, dermatologist.
São José do Rio Preto, SP, Brazil.

This is a case report in white paper format, described by Dermatologist Guilherme Bueno, from São José do Rio Preto, São Paulo, Brazil. Dr Guilherme has used the ETHEREA-MX® platform, with a ACROMA-QS® handpiece and in 532 nm.

Treatment:

- ▶ **Flat warts** present themselves as small brown papules and are commonly found on the face and on the dorsum of hands. The goal of the treatment is the destruction or removal of lesions. For this purpose, medical literature describes the use of topical medicaments, which provide chemical cauterization, as well as surgical procedures (electrocoagulation and curettage), cryotherapy (the destruction of lesions with liquid nitrogen) and LASER.
- ▶ **ACROMA-QS®**: LASER in QS, operating at a 20 nanosecond pulse time range, will guarantee high energy delivery in a short period of time. Working with 2 wavelengths, 1064 nm and 532 nm, the system allows for the treatment of melasma, tattoos, ochre dermatitis, among others.
- ▶ The use of LASER in 1064 nm is being widely indicated for telangiectasias as well as for larger caliber vases. Due to its selective absorption by the hemoglobin present in the vases, it will guarantee effectiveness with safety.
- ▶ Because of its photodisruptive effect when it touches the skin, that is, the light causes the explosion and fragmentation of the target tissue, LASER in q-switched ACROMA-QS® was chosen as a therapeutic option for the treatment of flat warts which are unresponsive to other treatments or other types of LASER.
- ▶ **5 sessions, in 30 day intervals were performed:**
1st session: spot 532 nm, 600 mj;
2nd, 3rd and 4th sessions: spot 532 nm, 1200 mj;
5th session: spot 532 nm, 1500 mj.

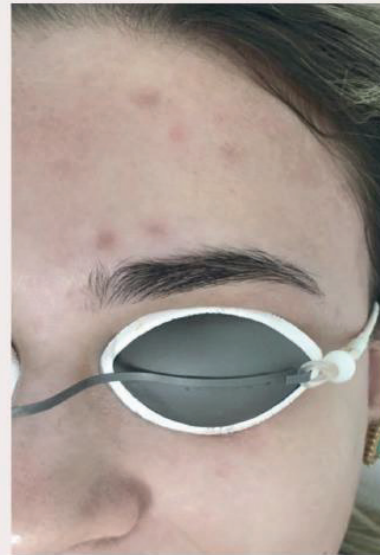

Imagem A: Pre-treatment.

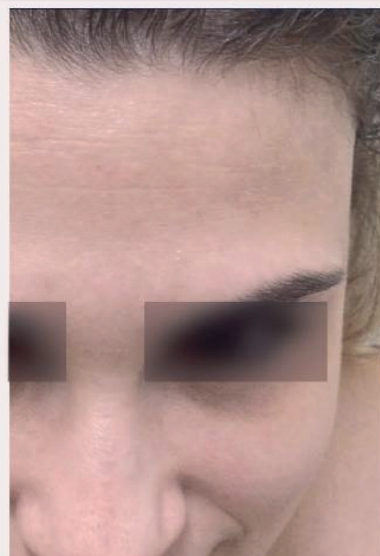

Imagem A: Post-treatment.



Case Report:

Q-switched LASER to treat nevus on the back.

Valeria Taborda, dermatologist
Bauru, SP, Brazil.

White paper case report described by dermatologist Valeria Taborda, from Bauru, SP, Brazil. Dr. Taborda used the ETHEREA-MX® platform with the ACROMA-QS® handpiece.

Therapy:

- ▶ ACROMA-QS®: LASER featuring 2 Nd:YAG RODs with wavelengths at 1064 nm and 532 nm.
- ▶ Q-switched LASERs have been referenced in literature as a tool for the therapeutic approach of several unaesthetic lesions of pigmented origin.
- ▶ By using a short pulse time (nanoseconds), it allows for a light-and-tissue photomechanical interaction, that is, a high-power mechanical disruption of the melanin pigment, but with little thermal damage
- ▶ In the given case, the chosen wavelength of 532 nm allowed treatment of the nevus, even with a progressive decrease in the amount of pigment, up to satisfactory extent.
- ▶ Treatment sessions were carried out, with increased power following lesion whitening:
3 mm spot, 532 nm, 600 mj, 5 Hz
3 mm spot, 532 nm, 900 mj, 5 Hz
Last sessions:
3 mm spot, 532 nm, 1200 mj, 5 Hz.



Image 1: Pretreatment evaluation.

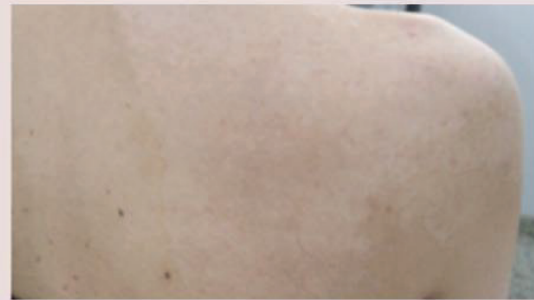

Image 2: Result after 22 sessions using ACROMA-QS®.

ACROMA-QS® is a LASER that works in QS, with fixed pulse time at 20 ns, thus delivering a great amount of energy in a short period of time (photoacoustic effect). Its spots feature wavelengths at 1064 nm and 532 nm, thus allowing for a greater treatment amplitude. It also features 2 LASER RODs for greater power. **Recommended for toning, tattoo removal, pigmented lesions and melasma treatments.**



Case Report:

Vascular spider treatment with ETHEREA-MX® and LongPulse® handpiece.

Adriano Carvalho Guimarães, angiologist and vascular surgeon, Santo Antônio da Platina, PR. Brazil.

White paper case report described by angiologist and vascular surgeon **Adriano Carvalho Guimarães**, from Santo Antônio da Platina, Paraná (PR), Brazil. The case is of a female patient complaining of possible vascular injury. Therapy comprised the use of the ETHEREA-MX® platform, with a LongPulse® handpiece, with no associations before, during or after treatment.

Therapy:

- ▶ The CLACS - Cryo-LASER & Cryo-Sclerotherapy (Miyake, et al) technique was used in the first session. The LASER treatment was carried out through the ETHEREA-MX® platform with the Nd:YAG handpiece at 1,064 nm (LongPulse®), associated with hypertonic glucose sclerotherapy and topical anesthesia conducted using refrigerated air cooling (SIBERIAN®) and aided by an augmented reality system.
- ▶ **Parameters used:** 1st treatment session, with 300 shots (approximately), fluency of 70 J/cm², pulse time of 15 ms and spot size of 6 mm plus 3 ml of hypertonic glucose.

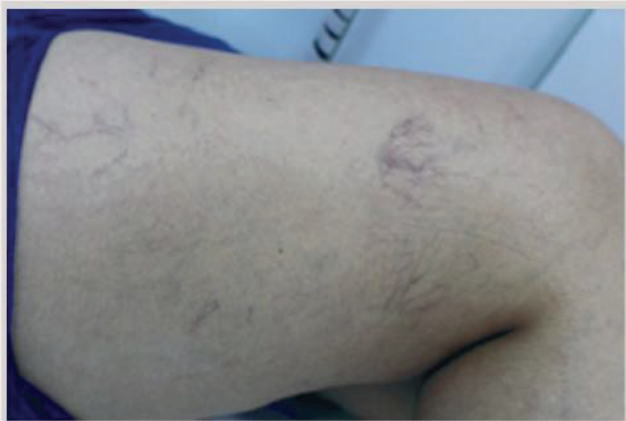

Image 1: Pre-treatment.

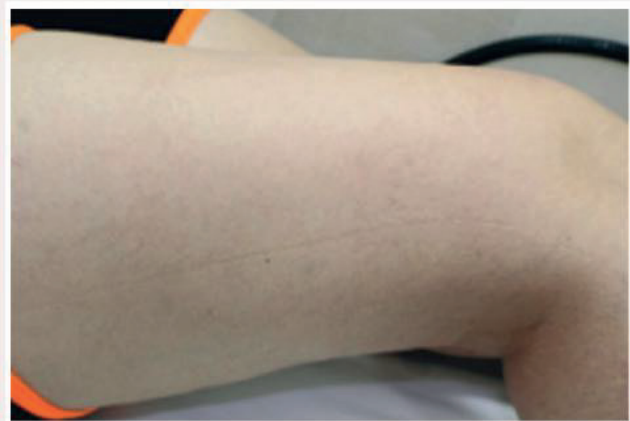

Image 2: Results after one treatment session.

Non-ablative LongPulse® fractional LASER treats subdermal collagen stimulation without the inconvenient post-treatment effects of non-ablative fractionated LASERs. Through the LASER fractionation principle, aimed at maintaining viable tissue areas within the treated areas, the idea is to allow and promote faster healing, thus reducing not only the relative downtime, but also the risk of related adverse effects, such as post-inflammatory hyperpigmentation.

Non-ablative fractionated LASER provides good results in the treatment of fine-to-moderate wrinkles and other signs of skin photoaging. Other recommendations commonly referenced in literature sources are those related to atrophic scars, acne scars, surgical scars, stretch marks and even melasma and pigment lesions.



Case Report:

Nd: YAG LASER for treating venous lake occurrences.

Flávia Pereira Reginatto, dermatologist
Passo Fundo, RS, Brazil.

White paper case report described by dermatologist Flavia Reginatto, from Passo Fundo, Rio Grande do Sul (RS), Brazil. Dr. Reginatto used the ETHEREA-MX[®], platform with the LongPulse[®] handpiece.

Tratamento:

- ▶ **Venous lake:** varicose veins, that is, vascular ectasias (dilations) that occur on the lips. They are asymptomatic, but cause great aesthetic discomfort.
- ▶ LongPulse[®]: Nd: YAG LASER is the most recommended wavelength for transdermal treatment of limb and face vascular lesions.
- ▶ The type of LASER used in this work is absorbed by hemoglobin, leading to a process of vessel coagulation with a consequent excision of the lesion.
- ▶ The procedure causes little pain and/or discomfort. The number of sessions for an ideal and definitive outcome may vary from 1 to 5, carried out monthly.
- ▶ In the given case, the therapeutic choice for laser proved to be effective and safer than other options to treat hemangioma in the oral cavity (sclerotherapy and surgery), commonly used and described in literature.
- ▶ 1 session was performed, LongPulse[®], 6 mm spot, 90 J/cm², 20 ms.

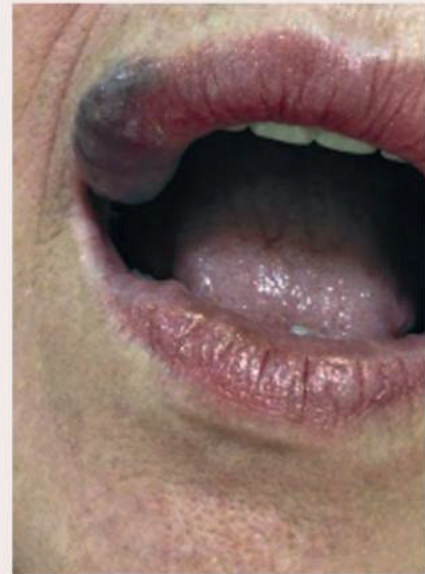

Image A: Pre-treatment.

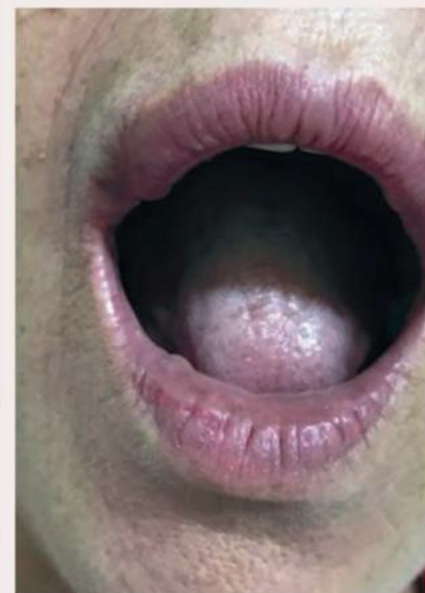
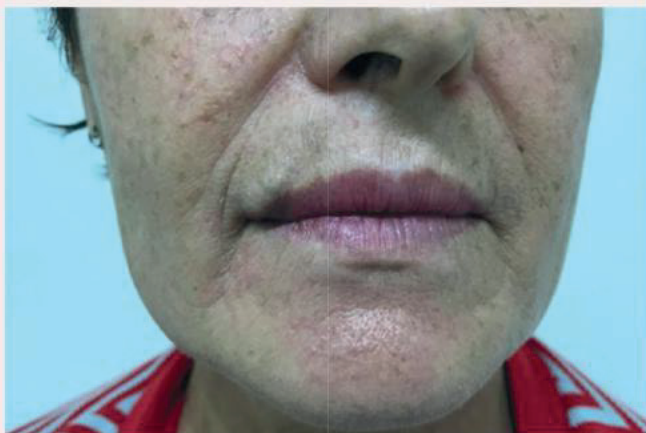
Image B: After one treatment session.



After-treatment photo.



Case Report:

Rejuvenation and lip enhancement with LASER
Nd:YAP 1340 nm

Gilvana Bonella, dermatologist
Passo Fundo, RS, Brazil

This is a case report in white paper format, described by dermatologist Gilvana Bonella, from Passo Fundo, RS, Brazil. Dr Gilvana used the **ETHEREA-MX®**, with a **1340 ProDeep®** handpiece.

Treatment:

- ▶ The demand for lip enhancement has been growing nowadays. With age increase, this region loses volume, becoming flaccid, which might lead to the development of wrinkles. There are several therapeutic options for the rejuvenation of lips, which may range from the necessities of teenagers to the correction of more severe cases. These procedures include plastic surgery, filling (with the use of fat or hyaluronic acid) and more recently, LASER.
- ▶ The 1340 nm wavelength, achieved by the Nd:YAP LASER, has little water absorption. Thus, it is one of the available wavelengths with greater skin penetration for collagen stimulus. Its selective water absorption allows, for example, for the treatment of wrinkles, stretch marks, and acne scars, with great safety. Even in patients with higher phototypes.
- ▶ **1340 ProDeep®** is a non-ablative fractional LASER. Its use has already been described in medical literature, for the treatment of unaesthetic scars, cystic-nodular acne and hidrosadenite. All with interesting results.
- ▶ In this case, Dr Gilvana has used 1340 ProDeep®, as an option for lip enhancement treatment in a younger patient. There is a previous instance of ablative LASER for this end.
- ▶ **Parameters used:**
Spot 8mm with a 100 mtz: 11 ml/mtz – 4 passes.
4 treatment sessions were carried out.

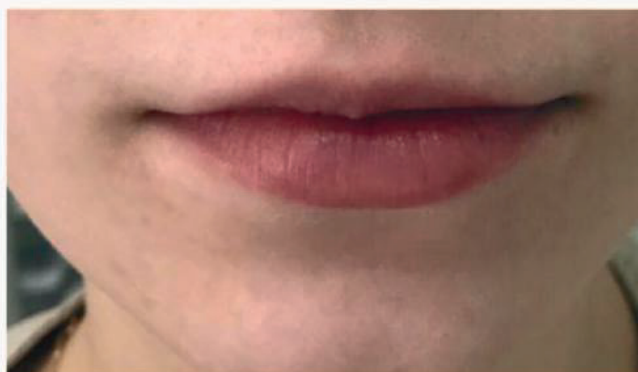


Image 1: Before.

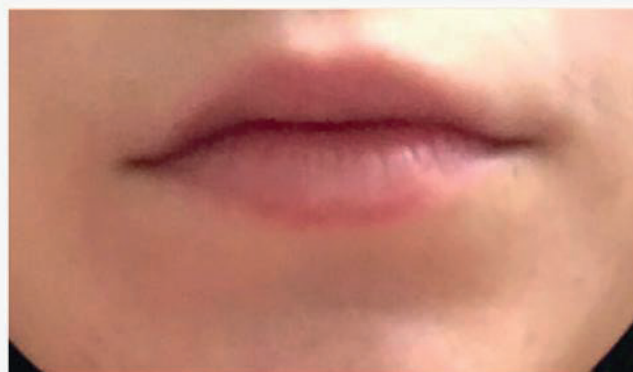


Image 2: After



Case Report:

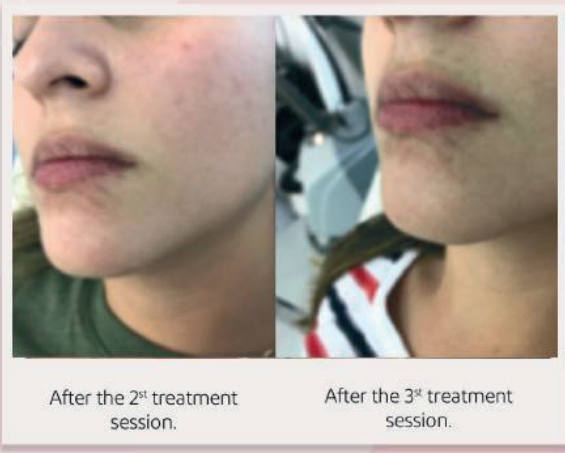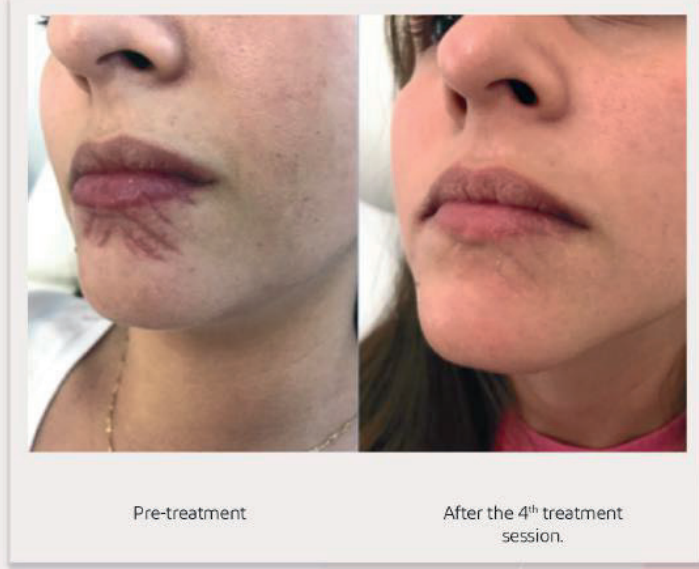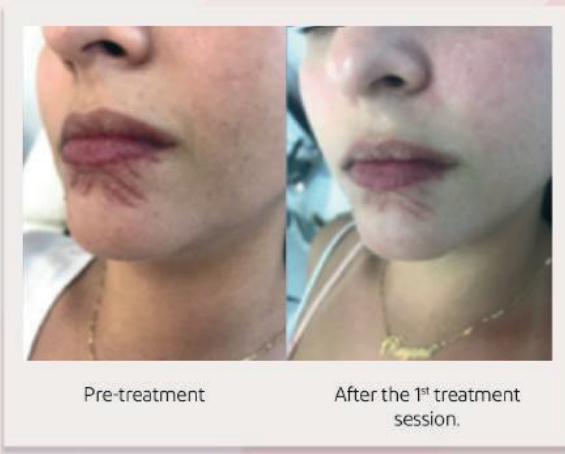Traumatic scar treatment using ETHEREA-MX[®] with the ProDeep[®] handpiece.

Bruna Lenz, dermatologist
Belo Horizonte, MG, Brazil.

White paper case report described by dermatologist Bruna Lenz, from Belo Horizonte, Minas Gerais (MG), Brazil. The given case is of a patient complaining of traumatic scarring. Therapy comprised the use of the ETHEREA-MX[®] platform with the ProDeep[®] handpiece, with no associations before, during or after treatment. The non-ablative ProDeep[®] fractional LASER treats subdermal collagen stimulation without the in convenient post-treatment effects of non-ablative fractionated LASERS.

Therapy:

- ▶ **1st session:** Carried out on October 26, 2017, with spot 8/100 mtz/cm² and 115 mJ/mtz with pulse time of 5 ms;
- ▶ **2nd session:** 30 days after the first, with spot 8/100 mtz/cm² and 125 mJ/mtz with time pulse of 5 ms;
- ▶ **3rd session:** Also 30 days after the second, with spot 8/100 mtz/cm² and 135 mJ/mtz with time pulse of 5 ms;
- ▶ **4th session:** A little more than 30 days after the third treatment session, with spot 8/100 mtz/cm² and 140 mJ/mtz with pulse time of 5 ms.





Case Report:

Nd:YAG 1064 micro pulse on chronic ulcer.

Bruno Ferraz, angiologist and vascular surgeon
Balneário Camboriú, SC, Brazil

This is a case report, in white paper format, as described by angiologist and surgeon **Dr. Bruno Ferraz** from Balneário Camboriú, SC, Brazil. Dr. Bruno used the ETHEREA-MX® with LongPulse® 1064 nm handpiece.

Treatment:

- ▶ **Diabetic patients** tend to present micro and macro vascular complications and these favor the development of venous disease. The evolution of this pathology (associated to diabetes or not), can cause ulcerations due to deficient local circulation, more predominant in extremities, with greater healing difficulty.
- ▶ The main methods used for the healing of ulcerations are compressive therapy, local treatment (including cleaning, disinfection and, if necessary, debridement), systemic medication and cyrgical treatment of the venous abnormality.
- ▶ The use of light to accelerate the healing process in ulcerations is described in medical literature wit the use of low power LED and LASERS. The use of 1064 nm wavelength in short pulses (in microseconds) allows for results that are closer to the photobiostimulation obtained through the above described technologies, when compared to selective photothermolysis, usually associated to the results obtained with LASER at 1064 nm.
- ▶ **Case description:** 63 year old patient, complaining of chronic ulcers on the dorsum of his left foot, with an 18 month evolution and no improvement with previous treatments. Personal background: Post-thrombotic syndrome with femoral and popilitic vein reflux, diabetes, hypertension, obesity and sedentarism.

Non invasive treatment: Venotonic and elastic compression. Topical, with hyaluronic acid at 2%. ..

- ▶ 11 LASER Nd:Yag 1064 nm LongPulse®, sessions were performed, with variable intervals between 2 to 16 days. The total time of the treatment was 70 days, with total epidermization of the ulcer, with no venous puncture and under the following parameters:

3 mm spot, 300 micros, 10 J/cm², 3 applications, with an average interval of 20 seconds between each one. Emphasis on the borders of the scars. The average number of shots was calculated based on the diameter of the ulcer (height x width).

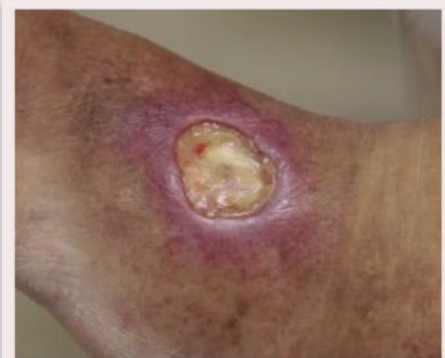

Image 1: Before

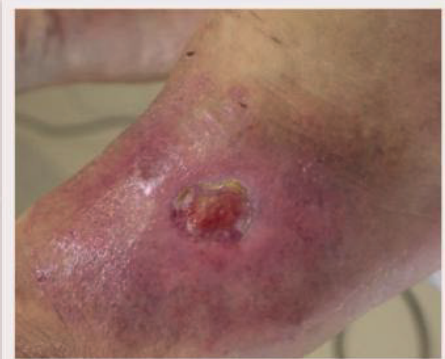

Image 2: 8 session - 45 days

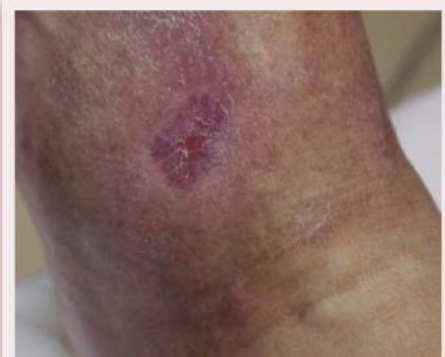

Image 3: Control.



Case Report:

Treating varicose veins on the lower limbs with long pulsed Nd:Yag LASER and sclerosant.

Rafael Pimenta, angiologist and vascular surgeon
Botucatu, SP, Brazil.

This is a case report in the form of a white paper by Dr. Rafael Pimenta, angiologist and vascular surgeon from Botucatu, SP, Brazil. Dr. Rafael used the ETHEREA-MX® platform with the LongPulse® handpiece.

Treatment:

- ▶ **Varicose veins in the lower limbs** are dilated superficial veins, with an alteration in the blood flow and direction. Due to the inefficiency of the circulation, a person who has varicose veins may present symptoms such as pain, burning and a heavy sensation. There may be fibrosis formation of the subcutaneous cellular tissue, ulcers and a predisposition for thrombosis.
- ▶ Treatment of varicose veins in the lower limbs varies from reducing symptoms by using compression stockings and medications. But removing varicose veins through a surgical procedure is often the most indicated treatment. This procedure may be done by sclerotherapy, conventional surgery or by use of LASER. Combining techniques frequently optimizes results, reduces risk as well as the number of sessions.
- ▶ Using the 1064 nm LASER has been widely indicated in both telangiectasias as well as larger caliber veins. As the absorption is selective for the hemoglobin present in the veins, effectiveness and safety are guaranteed. The ETHEREA-MX® LongPulse® handpiece has 3 spot sizes which guarantee different penetrations. Allowing the delivery of high energy at different pulse times facilitates the correct choice of parameters for an effective result in different cases of vascular lesions, in both lower limbs and the face.
- ▶ **For this case, treatments were combined using the following parameters:**
Sclerotherapy with foam 0.5% - 10 ml followed by LASER LongPulse®, spot size 6 mm, 40 ms e 70J/cm² with 97 shots.

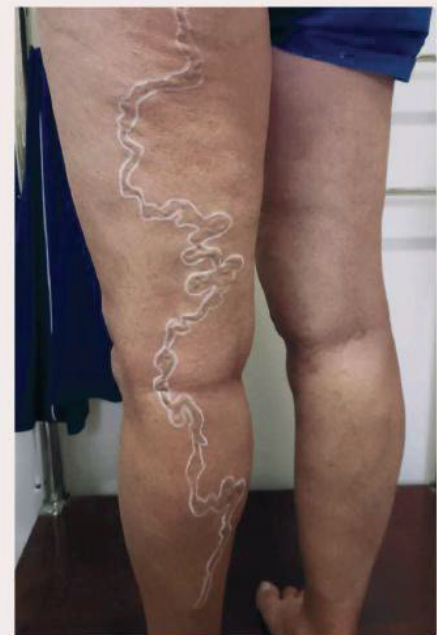

Image 1: Pre-treatment

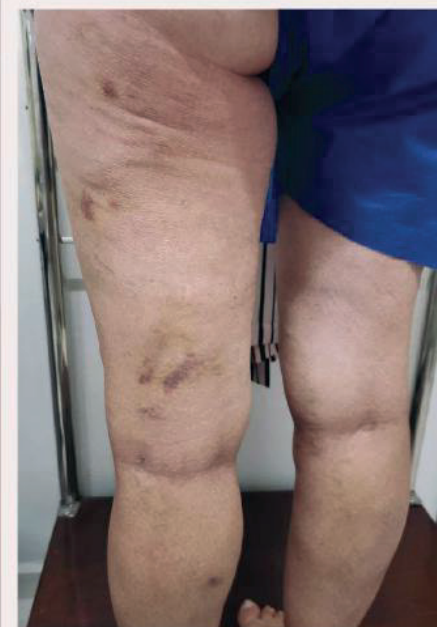

Image 2: Post-treatment



Case Report:

Er:YAG for treating and plumping lips.

Clessya Rocha, dermatologist
Jequié, BA, Brazil

This is a case report in the form of a white paper by Dr. Clessya Rocha, dermatologist, from Jequié, BA, Brazil. Dr. Clessya used the ETHEREA—MX® platform with the DualMode® handpiece and InLift® applicator.

Treatment:

- ▶ **DualMode®:** is a solid-state LASER from Er:YAG.
- ▶ The wavelength generated by this LASER (2940 nm) is strongly absorbed by water and therefore it is ablative. The presence of optical or mechanical fractioners makes treatment in the doctor's office possible, with very little downtime.
- ▶ The InLift applicator works with a pulse in smooth mode and each time it fires, there is a sequence of pulses with 8 intervals, mitigating the effect of ablation. The result is a long pulse of 400 ms, producing a greater collagen stimulation and lower tissue vaporization.
- ▶ This applicator can be used for intra-oral and lip treatment. It is also indicated for vaginal rejuvenation, both internal and external structures.

Parameters used: 45 mJ/mtz in fractional mode, with 100 shots on each side and an interval of 2 weeks between sessions. There were 4 treatment sessions.

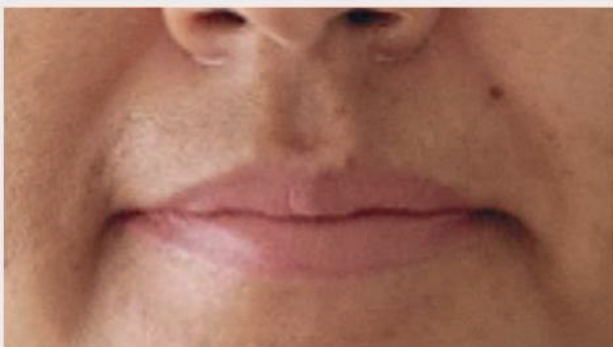


Image 1: pre-treatment evaluation

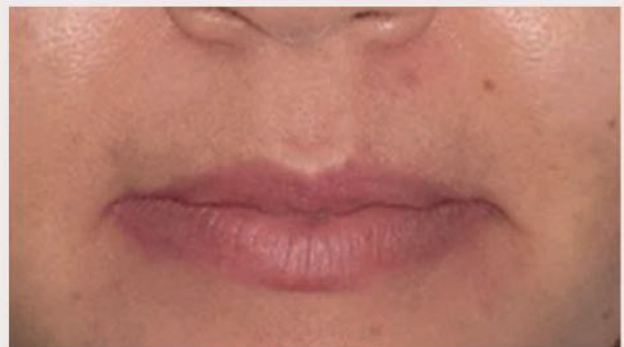


Image 2: Result after 4 sessions with DualMode



Case Report:

Er:YAG for treating pigmented lesions on the face and neck, resistant to other treatments

Luciena Cegatto Martins Ortigosa, dermatologist
Presidente Prudente, SP, Brazil.

This is a case report in the form of a white paper by Dr. Luciena Cegatto Martins Ortigosa, from Presidente Prudente, SP, Brazil. Dr. Luciena used the ETHEREA-MX® platform, with the 2940 DualMode® handpiece.

Treatment:

- ▶ The Er:YAG LASER output is strongly absorbed by water (10 times more than CO2 LASER). For this reason, the 2940 wavelength generated is ablative and superficial, allowing for safer treatment in the face and neck regions.
- ▶ The ETHEREA-MX® DualMode® handpiece allows for combined treatments, with short pulses (μ s) in milliseconds, and double pulse, leading to a deeper penetration of the LASER with a lower risk for hyperpigmentation.
- ▶ Short pulses – in microseconds – known as cold erbium, guarantee pure ablative LASER action, without producing heat.
- ▶ LASER ablation obtained when using DualMode® helps treat pigmented lesions. During the healing process, pigment extrusion occurs. In addition to this advantage, as described in literature, ablative LASERS facilitate drug delivery.
- ▶ The patient who was treated reported having pigmented lesions on her face and neck for many years, having had no response to topical treatments. After clinical evaluation, one session of 2940 nm DualMode® was performed with drug delivery of retinoic acid 3%.
- ▶ **Parameters used:** Spot size 100 mtz, 300 μ s 10 J/cm² + retinoic acid 3% immediate post-treatment.

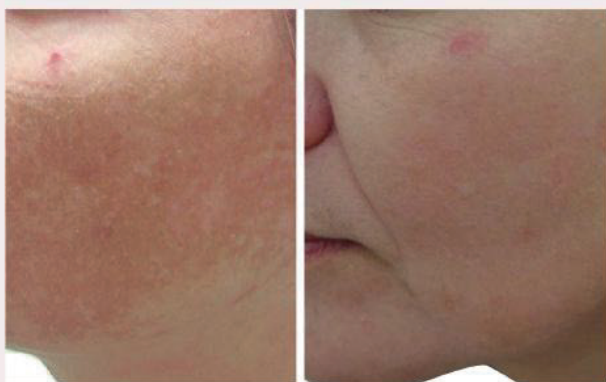

Image 1: Result after treatment on the face

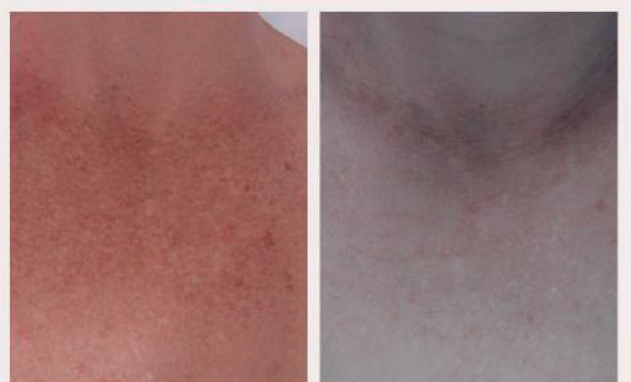

Image 2: Result after treatment on the neck



Case Report:

Treating a frontal vein with long pulse LASER Nd:YAG.

Livia Lyra, angiologist and vascular surgeon
Belo Horizonte, MG, Brazil.

This is a case report in the form of a white paper by Dr. Livia Lyra, angiologist and vascular surgeon from Belo Horizonte, MG, Brazil. Dr. Livia used the ETHEREA-MX® platform with the LongPulse® handpiece.

Treatment:

- ▶ The treatment of vascular lesions on the face are normally more complicated and must be better evaluated than vascular lesions on the limbs. On the face, for example, using sclerotherapy may cause a reflux of sclerosants to the arterioles, potentially resulting in serious complications such as necrosis in certain areas.
- ▶ Greater benefits from electrocoagulation are described in literature, however, even with this technology, adverse sequelae may appear in the skin due to the low selectivity for blood vessels.
- ▶ Use of the 1064 nm LASER has been largely indicated for photothermolysis, in other words, the selective absorption of light by the hemoglobin and relatively little absorption by melanin, therefore guaranteeing protection of the skin and surrounding tissue.
- ▶ LongPulse® ETHEREA-MX®: Nd:YAG LASER with wavelengths of 1064 nm, with an integrated cooling device. It permits transdermal treatment of veins on the face and limbs, with necessary specificity to guarantee safe results.
- ▶ Three sessions were performed with LongPulse® as follows:
 - Session 1: 6mm spot size, 30 ms and 90 J/cm²
 - Session 2: 6mm spot size, 30 ms e 90 J/cm²
 - Session 3: 6mm spot size, 20 ms e 80 J/cm²

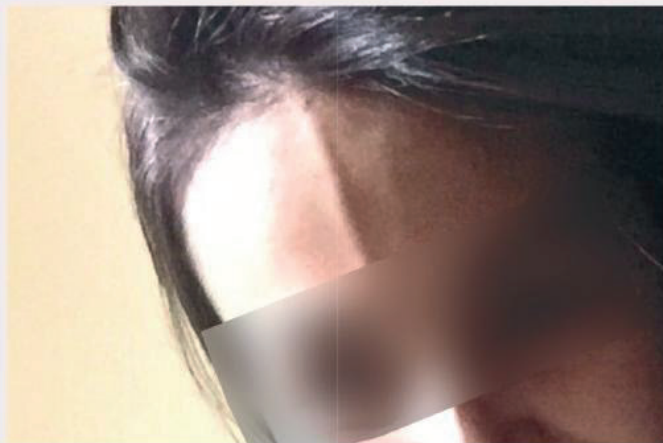

Image 1: Before treatment

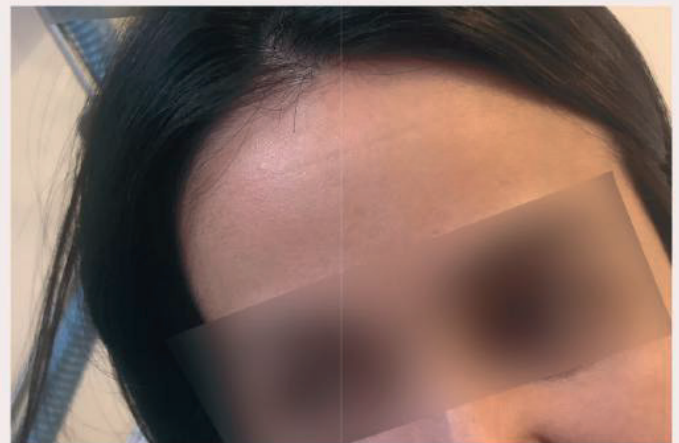

Image 2: After 3 sessions of treatment

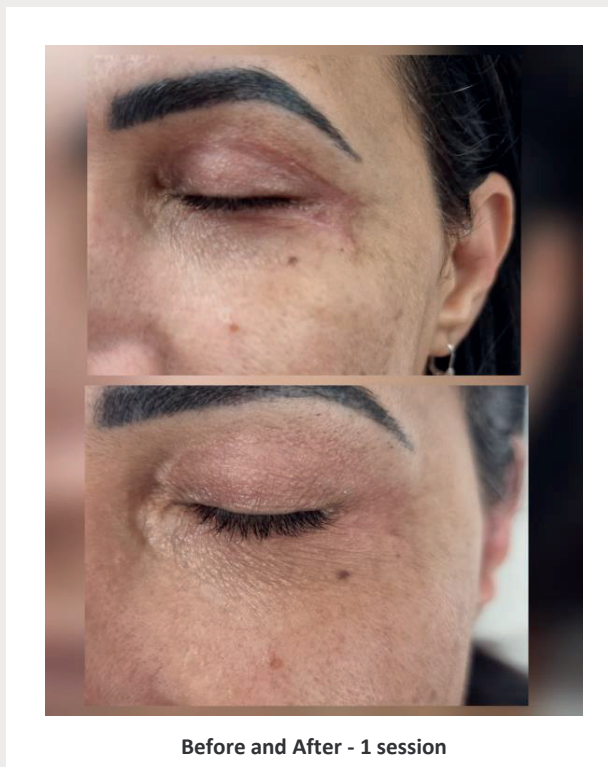

Case report:
Post-Surgical Scar Treatment with Er:Yag- DualMode®

Dr. Raed Khoury, Dermatologist
Kiryat Bialik, Israel

This is a treatment report carried out by the dermatologist Dr. Raed Khoury, from Kiryat Bialik, Israel, using the Etherea MX® platform, with the Dualmode® handpiece.

- ▶ Blepharoplasty is a surgical procedure used to treat eyelids excess skin, however during the tissue repair process, there may be unaesthetic scars formation.
- ▶ There are several treatments described to improve the scar appearance, ranging from creams and massages to non-ablative and also ablative fractional lasers.
- ▶ The DualMode® Handpiece, compatible with the ETHEREA-MX® and ZYE® platforms, works with the 2940nm – Er:Yag. It's an ablative fractional laser. Allows more aggressive treatments (in Dual mode - CO2 like) as well as less aggressive (single pulse). The selection of the ideal mode promotes positive results, which may vary according to the needs of each patient.
- ▶ Dr Raed performed 1 session, in Dual Mode, with the parameters described below.



Before and After - 1 session

HANDPIECE DualMode®
SPOT 8 mm – 100mtz
PULSE TIME 300 micros 5 ms
FLUENCE 12,5 mj/mtz 20mj/mtz



Case Report:

Combining treatments for best results: ProDeep® and DualMode® in the same session

Dr. Benjamin Collin, Aesthetic Medicine | Dudelange, Luxembourg

This is a treatment report carried out by Dr. Collin, using the ZYE ALX® platform, with the DualMode® and ProDeep® handpieces.

- ▶ Photoaging happens due to sun exposure, often during childhood, without adequate protection. Photoaged skin loses its shine and elasticity, has melanosis, freckles and fine or deep wrinkles and these characteristics can be seen even in young skin.
- ▶ The treatment can range from topical products to LASERS and light. The association of technologies with ablative and non-ablative laser guarantees action in different layers of the skin, providing a more efficient result with a smaller number of sessions.
- ▶ Dr. Collin combined two handpieces, compatibles with the ETHEREA-MX® and ZYE® platforms, to treat the pigmented lesions, redness and for collagen stimulation with good result in just one session.
- ▶ Starting with the ProDeep® handpiece (Nd:YAP 1340-nm), a non-ablative fractional LASER, with little absorption by water, treating the deeper layers of the skin. And then, the DualMode® handpiece (Er:YAG 2940-nm) an ablative fractional LASER, with high absorption by water, to treat the surface of the skin.

Handpiece	Mode	Spot	Pulse duration	Fluences	Passes
ProDeep®	-	8 mm/ 100 mtz	5 ms	110 mJ/mtz	1
DualMode®	DualMode	8 mm/ 100 mtz	300 µs 3 ms	12,5 mJ/mtz 20 mJ/mtz	1

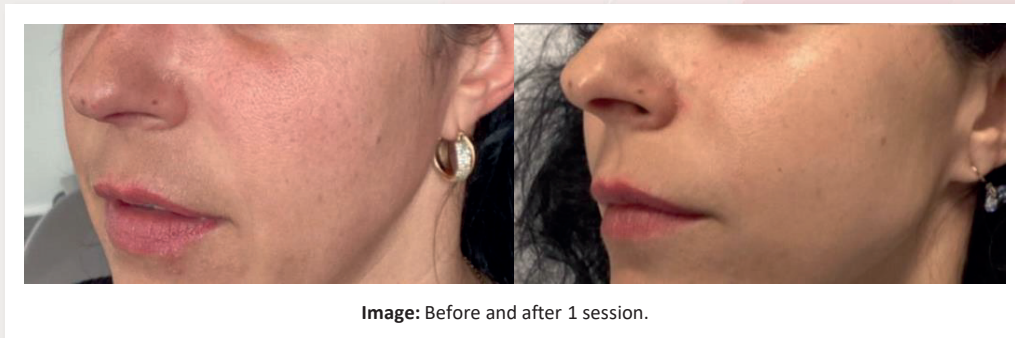


Image: Before and after 1 session.



Case Report: Tattoo removal combining Q-Switched LASER and SCULPTOR CO2

Célia Kalil, dermatologist
Porto Alegre - RS, Brazil

This is a white paper case report described by the dermatologist Dr. Célia Kalil, from Porto Alegre, Rio Grande do Sul, Brazil. Dr. Kalil used a combination of the **ACROMA-QS®**, **ETHEREA-MX®**, and **SCULPTOR CO2®** technologies.

Treatment:

- ▶ Tattoos are one of the best-known forms of body modification in the world. They are permanent art on the skin and technically consist of a dermic application that is frequently done at the subcutaneous level.
- ▶ **ACROMA-QS®**: LASER with two Nd:YAG rods, with waves measuring 1064 nm and 532 nm.
- ▶ **Q-SWITCHED LASER** is one of the most frequently used procedures to remove tattoos.
- ▶ **ACROMA-QS® Nd:YAG Q-SWITCHED (1064 nm)**: produces rapid pulses, breaking up the pigments, which will be expelled by the immune system.
- ▶ **SCULPTOR CO2** is an ablative fractional CO2 LASER that produces micro-zones of vaporization and coagulation in the skin.
- ▶ The combination of the **ACROMA-QS®** and **SCULPTOR CO2** technologies allows the pigments that are fragmented by the **ACROMA-QS®** to be expelled through the channels created by the **SCULPTOR CO2**, thereby reducing the number of sessions and preventing scars.

1st through 3rd treatment sessions:

ETHEREA-MX® ACROMA-QS® 1064 nm spot 7 mm 600-1200 mJ 5.0 Hz
SCULPTOR CO2 spot 300 mm, Random mode, Interval 0.3 s, Energy 100 mJ, Density 100 mtz/cm² and spot 800 mm, Brush mode, Energy 40 mJ, Frequency 200 mtz/cm².

4th through 5th treatment sessions:

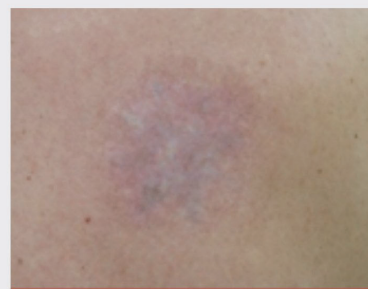ETHEREA-MX® ACROMA-QS® 1064 nm spot 5 e 3 mm 1.200 - 1.500 mJ
SCULPTOR CO2 spot 800 mm, modo Brush, Energy 40 mJ, Frequency 200 mtz/cm².

6th through 7th treatment sessions:

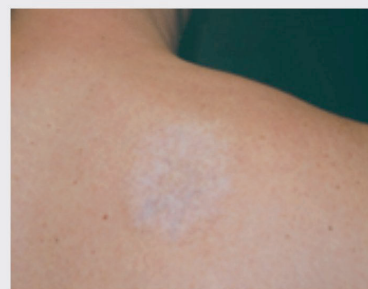SCULPTOR CO2 spot 800 mm, modo Brush, Energy 40 mJ, Frequency 150 mtz/cm².



Imagem 1: Pretreatment evaluation.



Img 2: After seven sessions.



Img 3: Follow-up two years after completion of treatment.



Case report:
Face photoaging treatment with IPL-Sq®

Emma Mills - Advanced Aesthetician, Oxford, UK.

Emma Mills - used the ETHEREA-MX® platform, with the IPL-Sq® handpiece.

- ▶ Photoaging, skin aging resulting from sun exposure over the years, causes the appearance of hyperpigmentation disorders such as melanoses and senile lentiginos, as well as vascular fragility and the presence of wrinkles.
- ▶ The photoaging treatment can range from chemical peels with depigmenting agents and antioxidants to LASERs, such as Q-Switched, CO2, Er:YAG or Intense Pulsed Light (IPL).
- ▶ The light emitted by the IPL is attracted to melanin present in the pigmented lesions and to hemoglobin present in the superficial vessels, causing heat production (selective photothermolysis) and, consequently, vessel closure and spot removal.
- ▶ The IPL-Sq® handpiece, compatible with the ETHEREA-MX® and ZYE® platforms, has a square pulse (Square-Wave Pulse®), a large pulse time variation (5-100 ms) and filters from 400 to 695 nm that allow treatment adjustment for patients with lighter or darker pigments safely and effectively.

Handpiece	Filter	Spot	Pulse time	Fluence
IPL-Sq®	540 nm	40x12 mm	15 ms	17 J/cm ²

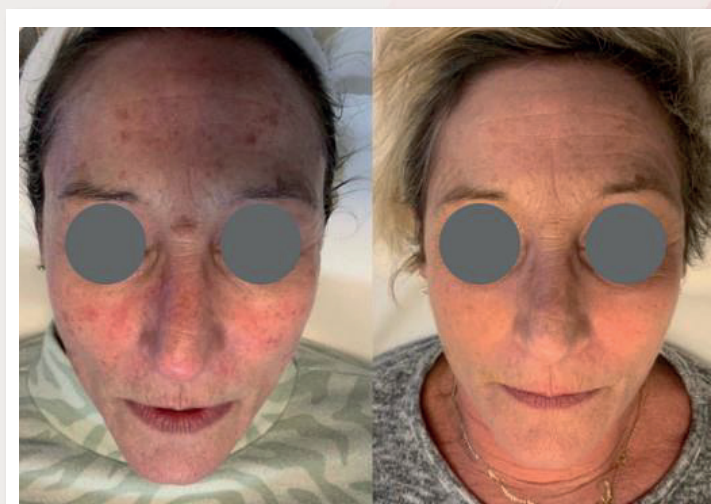

Image: Before and after 1 session



Case report:

Treatment of Xanthelasma with ACROMA-QS®.

Dr. Geann De Bortoli, Dermatologist, Curitiba, PR - Brazil.

Dr. Geann De Bortoli used the ETHEREA-MX® platform, with the ACROMA-QS® handpiece .

- ▶ Xanthelasma, or plane xanthomas, is a benign tumor of conjunctival origin resulting from the infiltration of xanthomatous cells into the dermis and the papillary body. It is characterized by the formation of dark yellow or brownish plaques, with a velvety, smooth or slightly grainy surface and with a soft consistency, located in the inner corners of the upper and lower eyelids.
- ▶ In most cases, the treatment for this type of lesion is based on aesthetic factors, with surgical removal and LASERs being the most widely used means. The 532 nm KTP LASER has been shown to be a good treatment option, with satisfactory results and a low rate of adverse effects, in the various published studies.
- ▶ The ACROMA-QS® handpiece, compatible with the ETHEREA-MX® and ZYE® platforms, is a Q-Switched LASER, with 20 ns pulses and widely versatile for having varied spots and 2 wavelengths: Nd:YAG 1064 nm and KTP 532 nm. The Nd:YAG 1064 nm is used for less aggressive treatments such as melasma, hyperchromia and dark tattoo removal, while the KTP 532 nm can be used for more aggressive treatments such as the removal of xanthelasma, flat keratosis and tattoos with lighter or warmer colors, such as red and orange.

Handpiece	Spot	Fluence	Nº of sessions	Interval
ACROMA-QS®	3 mm/ 532 nm	1,200 mJ	3	30 days

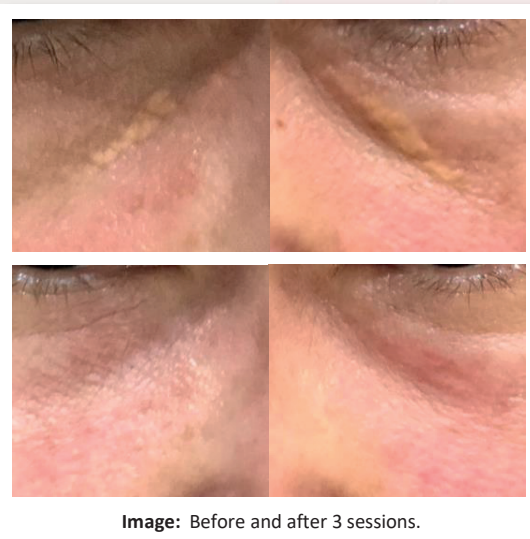


Image: Before and after 3 sessions.



Case report:

Treatment of vascular malformation in the face with IPL-Sq®

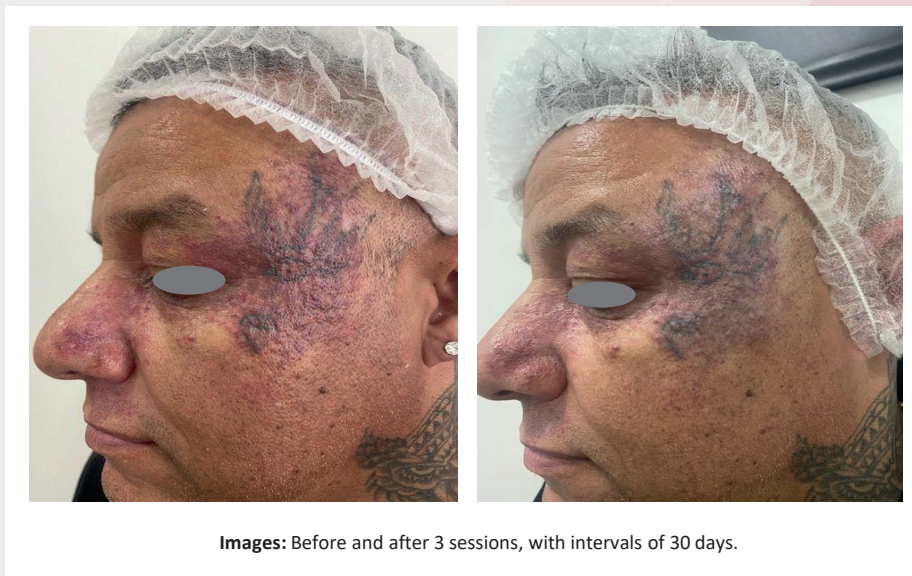Jenny Andrea Baquero Rey, Dermatologist
Buenos Aires, Argentina.

Dr. Jenny Rey used the ETHEREA-MX® platform, with the IPL-Sq® handpiece.


- ▶ Vascular malformations are changes in the development of blood vessels that may be related to arterial (arterial malformation), venous (venous malformation) or mixed (arteriovenous malformation) dysplasia and, when very apparent, may affect the patient's quality of life.
- ▶ The treatment of these face lesions is difficult to manage and, often, performed with the help of LASERs or intense pulsed light (IPL) aiming at their reduction and lightening.
- ▶ The light emitted by the IPL is attracted to hemoglobin present in this type of lesion, causing heat production (selective photothermolysis) and, consequently, closure of the most superficial vessels.
- ▶ The IPL-Sq® handpiece, compatible with the ETHEREA-MX® and ZYE® platforms, has a square pulse (Square-Wave Pulse®), a large pulse time variation (5-100 ms) and filters from 400 to 695 nm that allow treatment adjustment for patients with different types of vascular lesions in the face, neck and upper chest safely and effectively.

In this clinical case, it is noted that, although the patient has a tattoo overlapping the vascular lesion, he had a favorable response both clinically and in terms of aesthetic perception.

Handpiece	Filter	Spot	Pulse time	Fluence
IPL-Sq®	540 nm	40x12 mm	15 ms	17 J/cm ²
	540 nm	12x12 mm	15 ms	20 J/cm ²



Images: Before and after 3 sessions, with intervals of 30 days.



Case report:

Vascular lesions treatment and collagen stimulation with IPL-Sq®.

Dr. Anna Tomkowiak, Aesthetic medicine, Wroclaw - Poland.

Dr. Anna used the ETHEREA-MX® platform, with the IPL-Sq® handpiece .

- ▶ The presence of vessels on the face is a pathology most commonly seen in fair-skinned people and may or may not be associated with rosacea or skin aging. The treatment of this type of lesions can be done with the use of LASER (Nd:YAG 1064 nm) or Intense Pulsed Light – IPL.
- ▶ The light emitted by the IPL-Sq® handpiece is attracted to the hemoglobin present in the superficial vessels, generating heat (selective photothermolysis) and their consequent removal. In addition, the heat stimulates collagen production, reducing fine lines and contributing to skin rejuvenation.
- ▶ The IPL-Sq® handpiece, which is compatible with the ETHEREA-MX® and ZYE® platforms, has a Square-Wave Pulse®, large variation of pulse time (5-100 ms) and cut-off filters from 400 to 695 nm that allow the treatment to be safely and effectively adjusted for patients with superficial vessels.

Filter	Spot	Pulse Time	Fluence
580 nm	40x12 mm	20 ms	20 J/cm ²
540 nm	40x12 mm	10 ms	20 J/cm ²

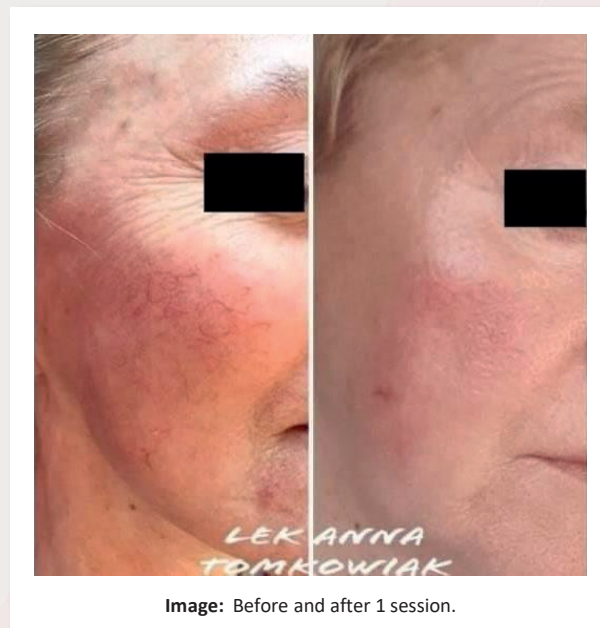

Image: Before and after 1 session.



CASE REPORT:

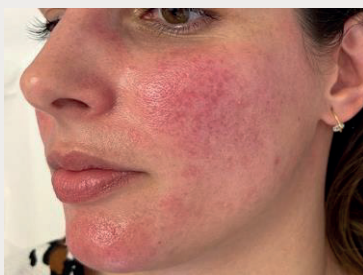Rosacea treatment with 1064nm micropulsed Laser – Dynamics®

Maria G. Gutierrez, Aesthetic Medicine, Santander, Cantabria, Spain.

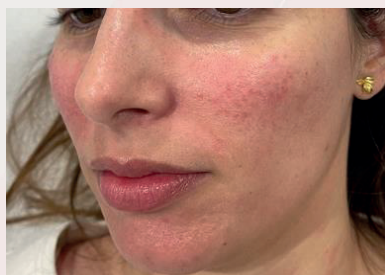Dr Gutierrez used the Etherea MX® platform, with the LongPulse® Handpiece in Dynamics® mode.

- Rosacea is a dermatological condition characterized by an alteration in the small blood vessels of the face and pilosebaceous units. It presents erythema of varying degrees, which may be associated with the appearance of pustules.
- Rosacea treatments vary according to the type and degree of the condition. Topical medications and creams that relieve skin irritation can be used, as well as dermabrasion, electrosurgery, or laser and light.
- The purpose of using the 1064nm micropulsed laser is to close microvessels, reducing erythema, as well as improving skin texture and closing pores.
- The LongPulse® handpiece, compatible with the Etherea MX® and Zye® platforms, works with long and short pulses (Dynamics® mode). Because it has a wavelength of 1064nm, the gold standard for the treatment of transdermal vascular lesions, it presents interesting results in rosacea.
- Dr Gutierrez performed 2 sessions, with an interval of 3 weeks. Drug delivery with Skinox Redness (Skymedic), LED Red (630 ± 10nm) and home therapy with dermocosmetics were associated.

SPOT	PULSE TIME	FLUENCY	FREQUENCY	NUMBER OF SHOTS
6mm	650 micros	8j/cm2	5HZ	1500
6mm	650 micros	10j/cm2	5Hz	1500



Before



After 1 session



After 2 sessions



Case Report:

Rejuvenation with a combination of LASERs: ProDeep® and DualMode®.

Dr. Ronen Magnun, Dermatologist | Beersheba, Israel

This is a treatment report carried out by Dr. Ronen Magnun using the ETHEREA-MX® platform with the ProDeep® and DualMode® handpieces.

- ▶ The signs of aging of the skin can be manifested through the presence of pigmented lesions, as keratosis, deep or superficial wrinkles and loss of elasticity.
- ▶ The association of ablative and non-ablative LASERs guarantees a more complete treatment with action on different layers of the skin, providing a more efficient result in a smaller number of sessions.
- ▶ Dr Ronen combined two handpieces compatibles with the ETHEREA-MX® and ZYE® platforms, to treat the wrinkles, keratosis and for collagen stimulation in this patient with thick skin.
- ▶ The ProDeep® handpiece (Nd:YAP 1340-nm) is a non-ablative fractional LASER with little absorption by water, being deeper than the others. And the DualMode® handpiece (Er:YAG 2940-nm) is an ablative fractional LASER with high absorption by water that allows for more aggressive treatments (in Dualmode pulse) to less aggressive ones (with single pulse).

Handpiece	Mode	Spot	Pulse duration	Fluence	Area	Passes
ProDeep®	-	8 mm/ 100mtz	5 ms	120 mJ/mtz	Full face	1
DualMode®	DualMode	8 mm/ 100mtz	300 µs 5 ms	15 mJ/mtz 35 mJ/mtz	Full face	2
DualMode®	DualMode	8 mm/ 100mtz	300 µs 5 ms	12 mJ/mtz 25 mJ/mtz	Eyelid	1

Session 1: ProDeep® + DualMode® / Session 2: DualMode® only.

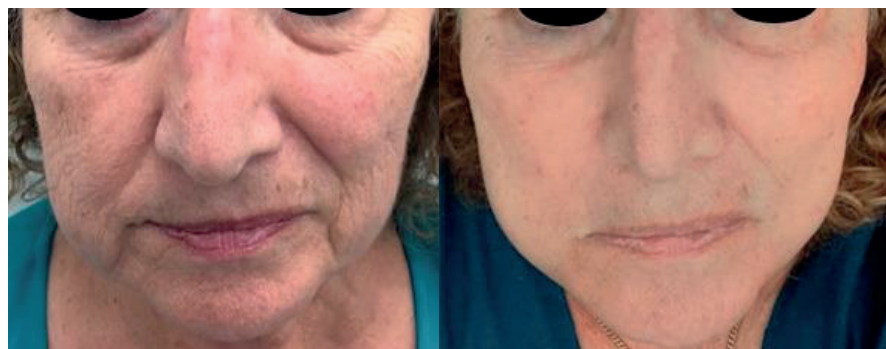

Image: Before and 2 months after 2 sessions.



Case Report:

Treatment of aged skin using a non-ablative fractional LASER:
ProDeep® 1340 nm.

Dr. Sabrina Legrand, Aesthetic Medicine | Béthune - France

This is a treatment report carried out by Dr. Sabrina Legrand using the ETHEREA-MX® platform with the ProDeep® handpiece.

- ▶ The signs of aging skin can be manifested through the presence of pigmented lesions, loss of elasticity and wrinkles. These can be deep and do not suffer any modification when they are stretched, or superficial, which can be altered or stretched.
- ▶ The treatment can range from topical products; to injectables, or lasers. The non-ablative fractional LASER is a good option providing an efficient result with a smaller risk of hyperpigmentation.
- ▶ The ProDeep® handpiece, compatible with the ETHEREA-MX® and ZYE® platforms, works with a wavelength of 1340nm – Nd:YAP. It is a non-ablative fractional LASER, with little absorption by water allowing rejuvenation of the skin. This includes the treatment of wrinkles, without restriction to phototypes and with little or no downtime.
- ▶ Dr. Legrand performed 3 sessions, with an interval of 30 days, using a cooling system coupled to the handpiece for safety and patient comfort. The parameters are described below.

Handpiece	Spot	Pulse duration	Fluence	Area	Passes
ProDeep	8 mm/ 100 mtz	3 ms	145 mJ/mtz	Full face	2

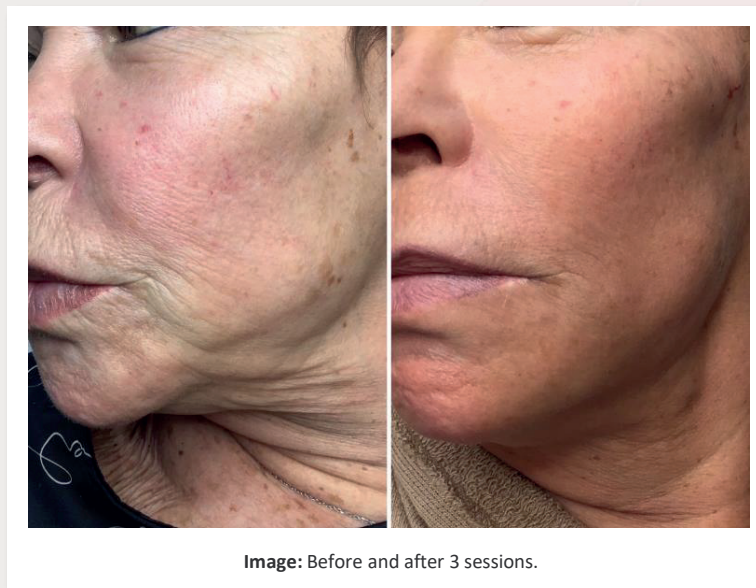

Image: Before and after 3 sessions.



Case report:

Treatment of localized scleroderma with IPL-Sq®

Dr. Tadeu Vasconcelos, Dermatologist, Santo André-SP, Brazil.

Dr. Tadeu Vasconcelos used the ETHEREA-MX® platform, with the IPL-Sq® handpiece.

- ▶ Localized scleroderma (LS) or morphea is a chronic connective tissue disease, of probable autoimmune etiology, that is based on alterations in collagen synthesis and deposition, represented clinically by sclerotic skin lesions/ plaques either with a yellowish or xanthochromic color.
- ▶ The pharmacological treatment of LS is a challenge, in general, aimed at suppressing inflammation and collagen alterations, as well as inhibiting events involved in the autoimmune process. Intense Pulsed Light (IPL) is also reported in the literature as a therapeutic resource in LS and should be considered.

The mechanism of action of LS treatment with IPL is not yet fully understood but a common theory is that the photobiomodulation, where light is converted into chemical energy, modulates cellular activity in the collagen and melanin synthesis, reduces inflammation and has immunomodulatory effect on lesional skin, restoring its function.

The IPL-Sq® handpiece, compatible with the ETHEREA-MX® and ZYE® platforms, has a square pulse (Square-Wave Pulse®), a large pulse time variation (5-100 ms) and filters from 400 to 695 nm allowing

Handpiece	Filter	Spot	Pulse time	Fluence
IPL-Sq®	400 nm	40x12 mm	40 ms	16 J/cm ²

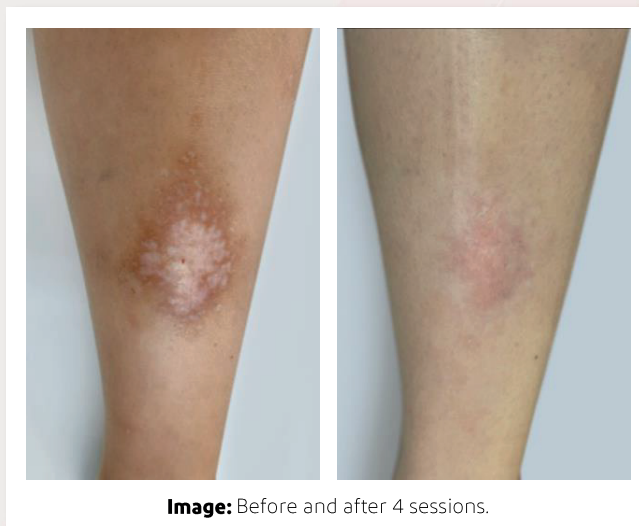

Image: Before and after 4 sessions.



Case report:

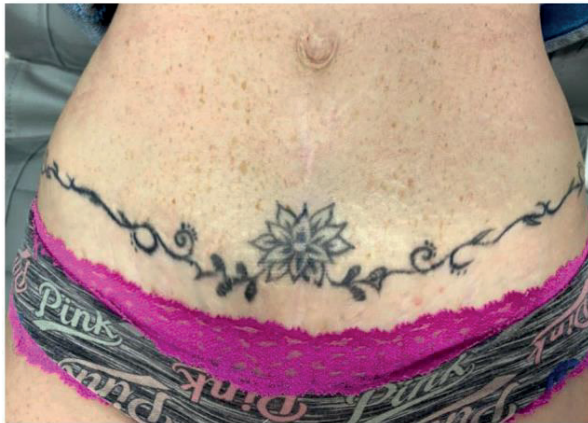
Tattoo removal with the ACROMA-QS® and DualMode® combination.

Dr. Marina Maldaner, Dermatologist
Assis- SP, Brazil

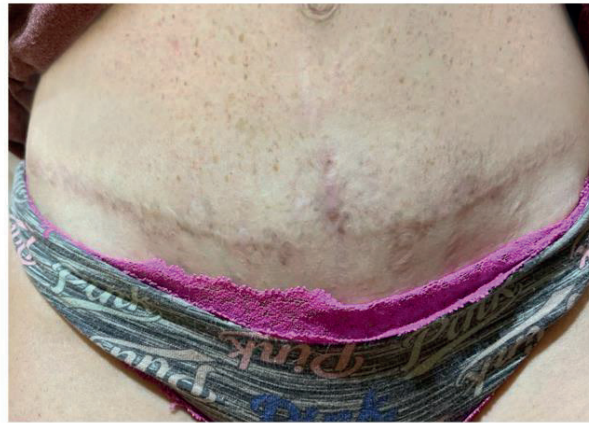This is a case report by Dr. Marina Maldaner, dermatologist from Assis (SP), Brazil using the ETHEREA-MX® platform, with the combination of two handpieces: ACROMA-QS® and DualMode®.

- ▶ It is common for a tattoo to be used to "hide" scars, however, this practice is not always conducive to desirable aesthetic results. In the case described the patient expressed her dissatisfaction and asked for the removal of the tattoo made over the scar.
- ▶ The ACROMA-QS® handpiece, compatible with the ETHEREA-MX® and ZYE® platforms is a 1064 nm ND:YAG laser and 532 nm KTP, Q-Switched, with pulses in 20 ns, very effective in removing pigmented lesions and tattoos. DualMode® is an Er:YAG ablative fractional LASER, with wavelength of 2940 nm and several indications.
- ▶ In the first three sessions, only the ACROMA-QS® LASER was used and, starting on the fourth session, the combination of ACROMA-QS® followed by DualMode® was applied in the same session to avoid the formation of a hypertrophic scar and overall improvement of the aesthetic aspect of the area. In the 3 days following the session, the patient used Cicaplast® associated with occlusive Drenison®.

HANDPIECE	MODO	SPOT	PULSE TIME	ENERGY/FLUENCE	PASSES
ACROMA-QS®	—	1064 nm / 5nm	20 ns	900 mJ in the first 3 sessions / 1500 mJ in the remaining sessions.	1
DualMode®	Single Mode	8/100 mtz/cm fractional	300 µs	12,5 mJ / mtz	1



Before



After



Case report:

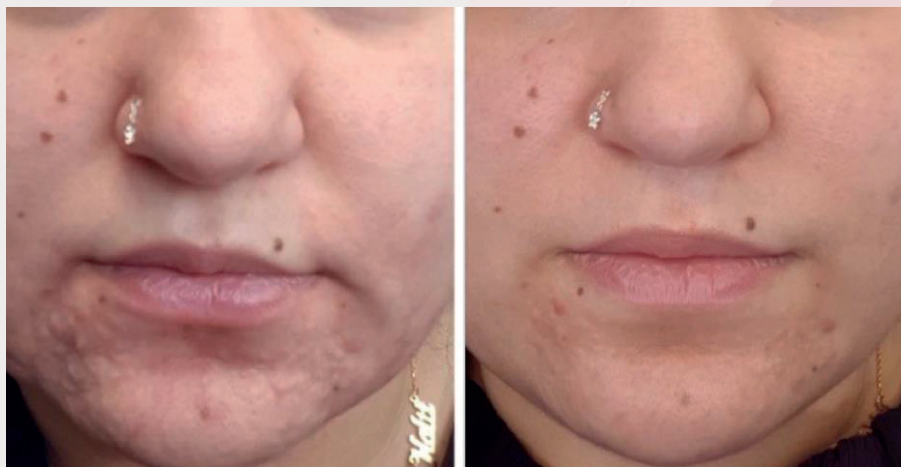Nd: Yap laser - ProDeep® - chin scar treatment.

Dr. Hugues Cartier, Dermatologist
Arras, France

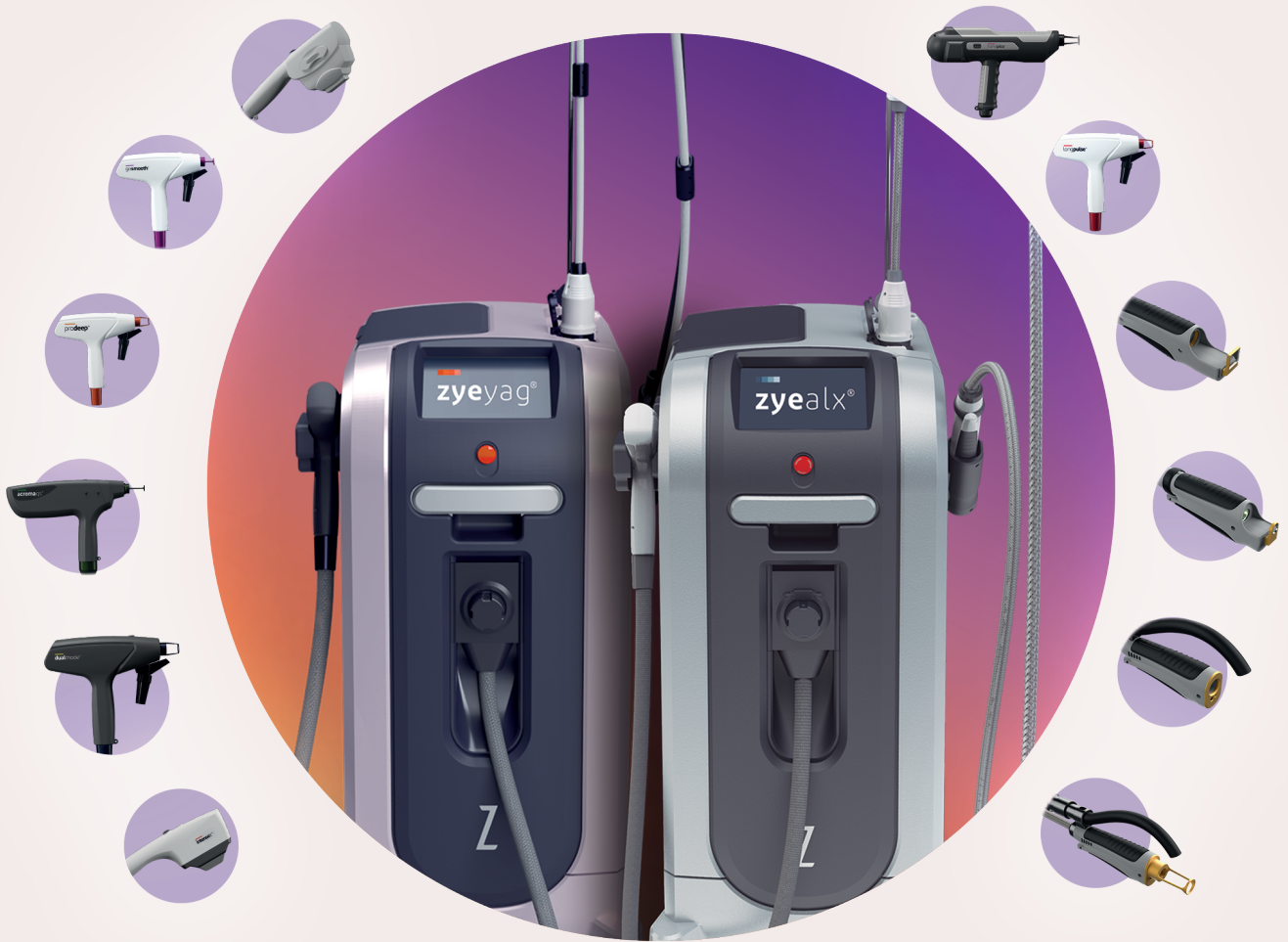This is a treatment report performed by the dermatologist Dr. Hugues Cartier, from Arras, France, using the Etherea MX® platform, with the ProDeep® handpiece.

- ▶ The unaesthetic scars can arise after burns, injuries, post-surgery or even after more severe cases of acne. The scars' location can directly affect a patient's quality of life.
- ▶ Among the treatments described in the literature to improve the scars appearance on the face are micro needling and ablative and non-ablative fractional LASERS.
- ▶ The ProDeep® handpiece, compatible with the ETHEREA-MX® and ZYE® platforms, works with a 1340nm wavelength – Nd:Yap. It is a non-ablative fractional laser, with small water absorption, being deeper than others. Allows for the treatment of recent and old scars, with no phototype restrictions and with little or no downtime.
- ▶ Dr Cartier held 2 sessions, with the parameters described below.

HANDPIECE	SPOT	PULSE TIME	FLUENCE
ProDeep®	8 mm – 100mtz	5 ms	110 mj/mtz



Before and After - 2 sessions



 **zyeyag**[®]  **zyealx**[®]

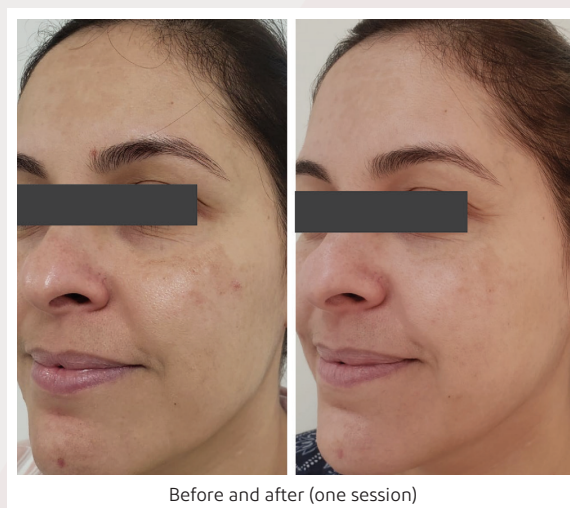

Case Report:
Melasma with rejuvenation

Adriana Cairo, dermatologist
São Paulo - SP, Brazil

This is a case report provided by the dermatologist Dr. Adriana Cairo, from São Paulo, SP, Brazil. The case described aims at a combination of treatments for global rejuvenation of the face without recovery time, using the **ZYE YAG®** platform at 1064 nm with the **ACROMA-QS®**, **IPL-Sq®** and **DualMode®** handpieces.

- ▶ Rejuvenation of the skin is a treatment that seeks to stimulate collagen, remove pigmentary lesions and even superficial vascular lesions. The idea is to attenuate lines and wrinkles, fight mild flaccidity, restore uniform coloration to the skin (removing undesired spots), as well as providing a toning effect and glow.
- ▶ The most modern technologies currently available are ablative fractional LASERS (for example: **DualMode®**), non-ablative fractional LASERS (for example: **ProDeep®**), nano (**ACROMA-QS®**) and picosecond LASERS, as well as those with longer and quasi-continuous pulses (**ZYE YAG® INTENSE®**).



Before and after (one session)

HANDPIECE/ SPOT	REGION	MODE	FLUENCE/ ENERGY	PULSE TIME	SHOTS	INDICATION
DualMode® inLift®	Intraoral	Fractional	30-40 mJ/mtz	Smooth Pulse	50-100/side	LASER lifting
5-15/LT 5 mm	Full face	Dynamics	10-12 J/cm ²	200-650 μs	500/quadrant	Thermal peeling for pores, lines and a vascular component
ACROMA-QS® 7 mm	Full face	-	600 mJ	-	2-3 passes	Clearing/melasma
DualMode® 12 mm	Full face	Dynamics	0.25-0.55 J/cm ²	200 μs	500/ quadrant	Clearing and drug delivery



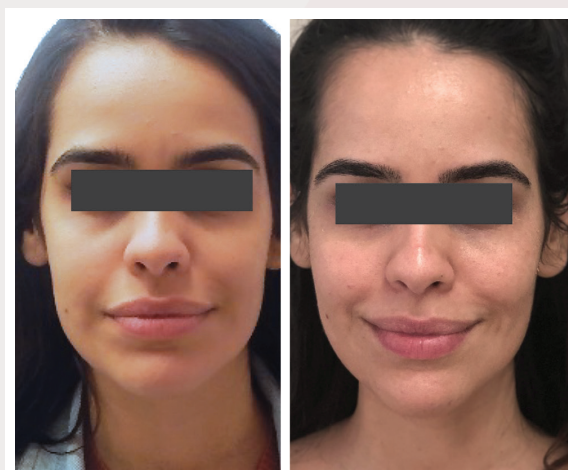Case Report:
Periorbital hyperchromia

Adriana Cairo, dermatologist
São Paulo - SP, Brazil

This is a case report provided by the dermatologist Dr. Adriana Cairo, from São Paulo, SP, Brazil. The case described aims at a combination of treatments for global rejuvenation of the face without recovery time, using the **ZYE YAG®** platform at 1064 nm with the **ACROMA-QS®**, **IPL-Sq®** and **DualMode®** handpieces.

▶ Rejuvenation of the skin is a treatment that seeks to stimulate collagen, remove pigmentary lesions and even superficial vascular lesions. The idea is to attenuate lines and wrinkles, fight mild flaccidity, restore uniform coloration to the skin (removing undesired spots), as well as providing a toning effect and glow.

▶ The most modern technologies currently available are ablative fractional LASERs (for example: **DualMode®**), non-ablative fractional LASERs (for example: **ProDeep®**), nano (**ACROMA-QS®**) and picosecond LASERs, as well as those with longer and quasi-continuous pulses (**ZYE YAG® INTENSE®**).



Before and after (one session)

HANDPIECE/ SPOT	REGION	FLUENCE/ ENERGY	PULSE TIME	SHOTS	INDICATION
IPL-Sq® Vascutip 12 mm/540 or 580 nm Filter	Eyelids	11-20 J/cm ²	10-20 ms	1 pass	Upper pigment clearing
ACROMA-QS® 7 mm	Full face	900 mJ	-	6-8 passes	LASER toning
ACROMA-QS® 9 mm/100 mtz	Eyelids	600 mJ-900 mJ	-	2 passes	Deep pigment clearing
DualMode® TrueLift®	Eyelids	15-20 mJ/mtz	Smooth Pulse	30 a 50/ eyelids	Clearing and drug delivery

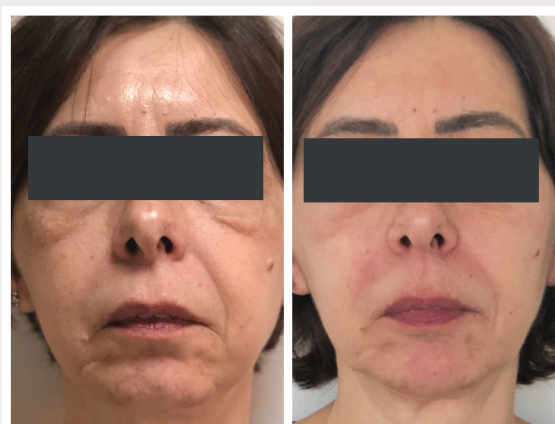

Case Report:
Rejuvenation without *downtime*

Adriana Cairo, dermatologist
São Paulo - SP, Brazil

This is a case report provided by the dermatologist Dr. Adriana Cairo, from São Paulo, SP, Brazil. The case described aims at a combination of treatments for global rejuvenation of the face without recovery time, using the **ZYE YAG®** platform at 1064 nm with the **5-15/LT** and **DualMode®** handpieces.

- ▶ Rejuvenation of the skin is a treatment that seeks to stimulate collagen, remove pigmentary lesions and even superficial vascular lesions. The idea is to attenuate lines and wrinkles, fight mild flaccidity, restore uniform coloration to the skin (removing undesired spots), as well as providing a toning effect and glow.
- ▶ The most modern technologies currently available are ablative fractional LASERS (**DualMode®**), non-ablative fractional LASERS (for example: **ProDeep®**), nano (**ACROMA-QS®**) and picosecond LASERS, as well as those with longer and quasi-continuous pulses (**ZYE YAG® INTENSE®**).



Before and after (four sessions)

HANDPIECE/ SPOT	REGION	MODE	FLUENCE/ENERGY	PULSE TIME	SHOTS	INDICATION
DualMode® inLift®	Intraoral	<i>Fractional</i>	30-40 mJ/mtz	Smooth Pulse	50-100/side	LASER lifting
5-15/LT 5 mm	Full face	<i>Dynamics</i>	8-20 J/cm ²	200-650 µs	1.000-2.000/ quadrant	Thermal peeling for pores and fine lines
DualMode® 12 mm	Full face	<i>Dynamics</i>	0.25-0.55 J/cm ²	200 µs	500-1.000 KJ/ quadrant	Clearing and drug delivery
5-15/LT 10 or 15 mm	Neck, chin and chest	<i>Intense</i>	20-30 W	15s (shot time)	7-10 KJ/ quadrant	Skin tightening

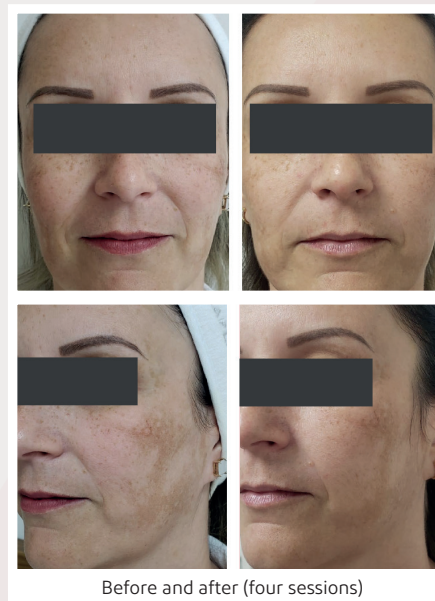

Case Report:
Rejuvenation without *downtime*

Adriana Cairo, dermatologist
São Paulo - SP, Brazil

This is a case report provided by the dermatologist Dr. Adriana Cairo, from São Paulo, SP, Brazil. The case described aims at a combination of treatments for global rejuvenation of the face without recovery time, using the **ZYE YAG®** platform at 1064 nm with the **5-15/LT** and **DualMode®** handpieces.

- ▶ Rejuvenation of the skin is a treatment that seeks to stimulate collagen, remove pigmentary lesions and even superficial vascular lesions. The idea is to attenuate lines and wrinkles, fight mild flaccidity, restore uniform coloration to the skin (removing undesired spots), as well as providing a toning effect and glow.
- ▶ The most modern technologies currently available are ablative fractional LASERs (**DualMode®**), non-ablative fractional LASERs (for example: **ProDeep®**), nano (**ACROMA-QS®**) and picosecond LASERs, as well as those with longer and quasi-continuous pulses (**ZYE YAG® INTENSE®**).



HANDPIECE/ SPOT	REGION	MODE	FLUENCE/ENERGY	PULSE TIME	SHOTS	INDICATION
DualMode® InLift®	Intraoral	Fractional	30-40 mJ/mtz	Smooth Pulse	50-100/side	LASER lifting
5-15/LT 5 mm	Full face	Dynamics	8-20 J/cm ²	200-650 μs	1.000-2.000/ quadrant	Thermal peeling for pores and fine lines
DualMode® 12 mm	Full face	Dynamics	0.25-0.55 J/cm ²	200 μs	500-1.000/ quadrant	Clearing and drug delivery
5-15/LT 10 or 15 mm	Neck, chin and chest	Intense	20-30 W	15s (shot time)	7-10 KJ/ quadrant	Skin tightening

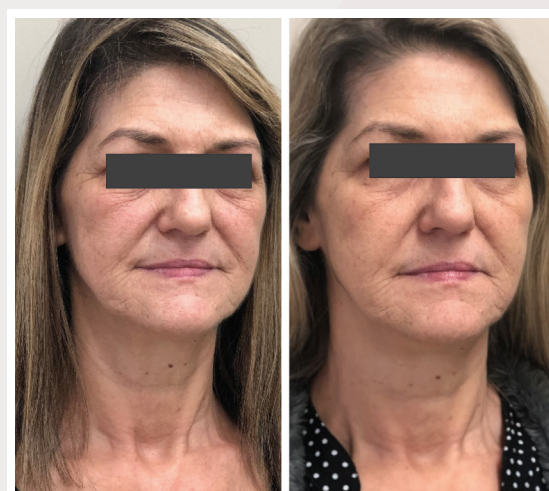

Case Report:
Solar elastosis

Adriana Cairo, dermatologist
São Paulo - SP, Brazil

This is a case report provided by the dermatologist Dr. Adriana Cairo, from São Paulo, SP, Brazil. The case described aims at a combination of treatments for global rejuvenation of the face without recovery time, using the **ZYE YAG®** platform at 1064 nm with the **5-15/LT**, **ProDeep®** and **DualMode®** handpieces.

- ▶ Rejuvenation of the skin is a treatment that seeks to stimulate collagen, remove pigmentary lesions and even superficial vascular lesions. The idea is to attenuate lines and wrinkles, fight mild flaccidity, restore uniform coloration to the skin (removing undesired spots), as well as providing a toning effect and glow.
- ▶ The most modern technologies currently available are ablative fractional LASERs (for example: **DualMode®**), non-ablative fractional LASERs (for example: **ProDeep®**), nano (**ACROMA-QS®**) and picosecond LASERs, as well as those with longer and quasi-continuous pulses (**ZYE YAG® INTENSE®**).



Before and after (four sessions)

HANDPIECE/ SPOT	REGION	MODE	FLUENCE/ENERGY	PULSE TIME	SHOTS	INDICATION
DualMode® inLift®	Lips	Fractional	35-40 mJ/mtz	Smooth Pulse	20 a 30/lip	Volumizing
ProDeep® 8 mm/100 mtz	Eyelids	-	70 mJ/mtz	3 ms	2 passes	Rejuvenation
ProDeep® 8 mm/100 mtz	Perioral wrinkles	-	90-100 m/mtz	3 ms	2 passes	Rejuvenation
5-15/LT 10 or 15 mm	Malar region	Intense	20-30 W	15s (time of shot)	6-7 KJ/ hemiface	Skin tightening
5-15/LT 10 or 15 mm	Neck	Intense	30 W	15s (time of shot)	7-10 KJ/ quadrant	Skin tightening
DualMode® 12 mm	Full face	Dynamics	0.25-0.55 J/cm²	200 µs	500-1.000/ quadrant	Clearing and drug delivery

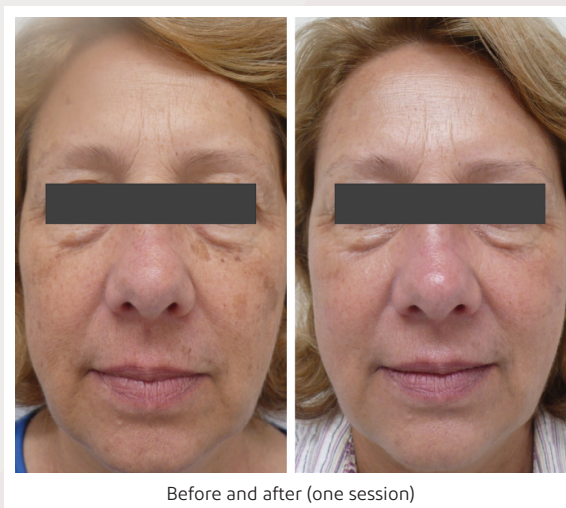

Case Report:
Solar melanosis

Adriana Cairo, dermatologist
São Paulo - SP, Brazil

This is a case report provided by the dermatologist Dr. Adriana Cairo, from São Paulo, SP, Brazil. The case described aims at a combination of treatments for global rejuvenation of the face without recovery time, using the **ZYE YAG®** platform at 1064 nm with the **ACROMA-QS®**, **IPL-Sq®** and **DualMode®** handpieces.

- ▶ Rejuvenation of the skin is a treatment that seeks to stimulate collagen, remove pigmentary lesions and even superficial vascular lesions. The idea is to attenuate lines and wrinkles, fight mild flaccidity, restore uniform coloration to the skin (removing undesired spots), as well as providing a toning effect and glow.
- ▶ The most modern technologies currently available are ablative fractional LASERs (for example: **DualMode®**), non-ablative fractional LASERs (for example: **ProDeep®**), nano (**ACROMA-QS®**) and picosecond LASERs, as well as those with longer and quasi-continuous pulses (**ZYE YAG® INTENSE®**).



HANDPIECE/ SPOT	REGION	MODE	FLUENCE/ ENERGY	PULSE TIME	SHOTS	INDICATION
IPL-Sq® 540 or 580 nm Filter	Full face	-	10-19 J/cm ²	10-20 ms	1 pass	Pigmentary lesions
ACROMA-QS® 7 mm	Full face	-	600-1200 mJ	-	2-3 passes	LASER toning
ACROMA-QS® KTP 532 nm 3 mm	Localized	-	600-900 mJ	-	1	Keratosis
DualMode® 12 mm	Full face	Dynamics	0,25-0,55 J/cm ²	200 µs	500/ quadrant	Clearing and drug delivery



Case Report:

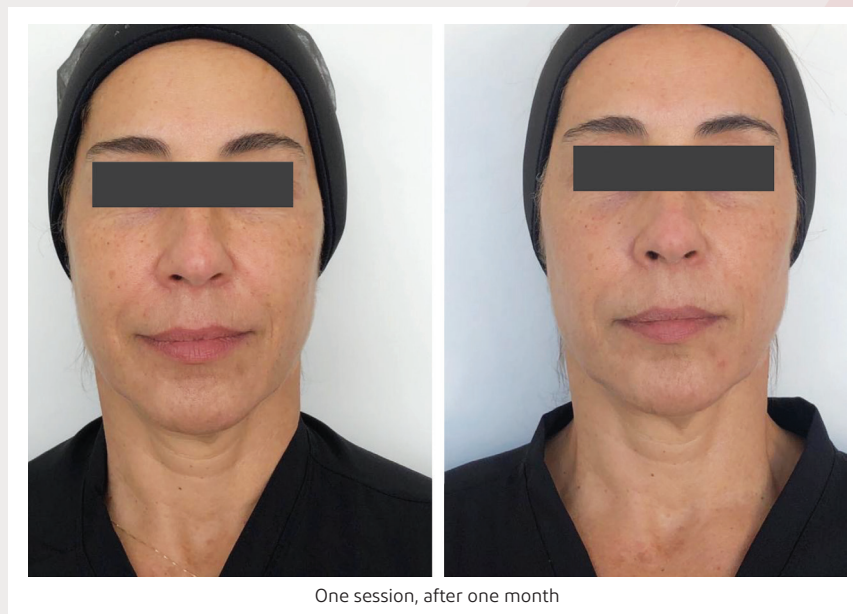ZYE ALX® 755 nm in Rejuvenation:
Lightening Spots and Toning Effect

Alexandre Filippo, dermatologist
Rio de Janeiro - RJ, Brazil

This is a case report provided by the dermatologist Dr. Alexandre Filippo, from Rio de Janeiro, RJ, Brazil. The case described is focused on general rejuvenation of the face, using the **ZYE ALX®** platform at 755 nm with the **3-10/VL** handpiece.

- ▶ Skin rejuvenation is a treatment that aims to stimulate collagen, remove pigmented lesions and even superficial vascular lesions. The idea is to attenuate lines and wrinkles, fight mild flaccidity, restore even coloring to the skin (removing undesired spots), as well as providing a toning effect and glow. The most modern technologies currently available include ablative fractional LASERs (for example: **DualMode®**), non-ablative fractional LASERs (for example: **ProDeep®**), nano (**ACROMA-QS®**) and picosecond LASERs, as well as those with longer and quasi-continuous pulses (**ZYE YAG® INTENSE®**).

HANDPIECE/SPOT	FLUENCE/ ENERGY	PULSE TIME	MODE
3-10/VL 6 mm	10 J/cm ²	650 ms	Dynamics



One session, after one month



Case Report:

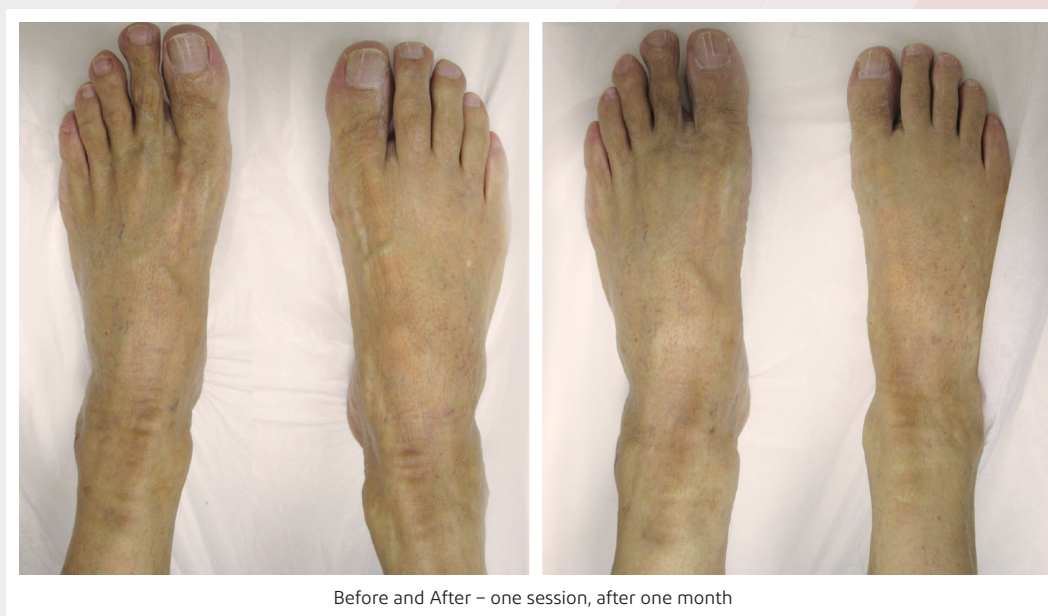ZYE ALX® 755 nm in the Treatment of Ochre Dermatitis

Alexandre Filippo, dermatologist
Rio de Janeiro - RJ, Brazil

This is a case report provided by the dermatologist Dr. Alexandre Filippo, from Rio de Janeiro, RJ, Brazil. The case described is the treatment of ochre dermatitis using the **ZYE ALX®** platform at 755 nm with the **3-10/VL** handpiece.

- ▶ Ochre dermatitis is an inflammation resulting from venous hypertension, which accumulates hemosiderin in the extravasation of the vessel of the affected region, resulting in an ochre coloration as a result of the combination of yellow with pink and black in a certain proportion. Current treatments include those done with q-switched LASER (**ACROMA-QS®**, available for the **ETHEREA-MX®** and **ZYE®** platforms) and with the ALEXANDRITA LASER at 755 nm (**ZYE ALX®**).

HANDPIECE/SPOT	FLUENCE/ ENERGY	PULSE TIME	MODE
3-10/VL 6mm	8 J/cm ²	300 ms	Dynamics



Before and After – one session, after one month



Case Report:

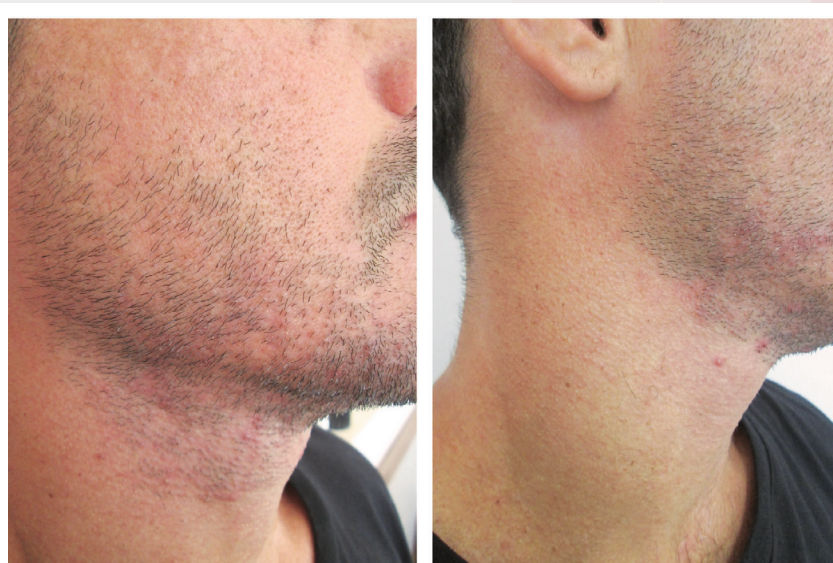ZYE ALX® 755 nm in the Treatment of Pseudofolliculitis Barbae

Alexandre Filippo, dermatologist
Rio de Janeiro - RJ, Brazil


This is a case report provided by the dermatologist Dr. Alexandre Filippo, from Rio de Janeiro, RJ, Brazil. The case described is the treatment of pseudofolliculitis barbae using the **ZYE ALX®** platform at 755 nm with the **8-18/HR** handpiece.

- ▶ Hair removal was one of the first aesthetic indications for LASER use in medicine. To the present, the efficacy and safety of LASER hair removal is widely supported by extensive clinical literature. More modern LASERs, with longer pulse times, wavelengths more closely matching the melanin in the skin and highly efficient contact cooling systems (**COOL-&-CLEAR®**) allow the treatment of all skin tones without risk of adverse effects (**ZYE ALX®**).

HANDPIECE/SPOT	FLUENCE/ ENERGY	PULSE TIME	MODE
8-18/HR 8 mm	12 J/cm ²	30 ms	Static



One session, after one month

**Case Report:**

ZYE YAG® 1064 nm in the Treatment of Vascular Lesions
in the Lower Extremities

Carlos Eduardo de Freitas Jorge, vascular surgeon
Belo Horizonte - MG, Brazil

This is a case report provided by the vascular surgeon Dr. Carlos Eduardo de Freitas Jorge, from Belo Horizonte, MG, Brazil, using the **ZYE YAG®** platform at 1064 nm with the **3-10/VL** handpiece.

- ▶ The **LongPulse®** fractional, non-ablative LASER generates the stimulation of subdermal collagen without the inconvenience of the posttreatment effects of fractional, non-ablative LASERs. Through the fractional LASER principle, which seeks to maintain the good condition of the tissue in the treated areas, the idea is to promote faster recovery, as well as reducing not only relative downtime, but also the relative risk of adverse effects, such as post-inflammatory hyperpigmentation.
- ▶ The ablative fractional LASER generates good results in the treatment of fine and moderate wrinkles, as well as other signs of aging caused by exposure to sunlight. Other treatment recommendations commonly reported in bibliographic sources are atrophic scars, acne scars, surgical scars, stretch marks and even melasma and pigmentary lesions.
- ▶ **ZYE YAG®** LASER technology at 1064 nm, together with the **3-10/VL** handpiece, with sapphire window cooling (**COOL-&-CLEAR®** system), allows transdermic treatment of veins on the face and extremities, with the specificity necessary to ensure safe results.

HANDPIECE/SPOT

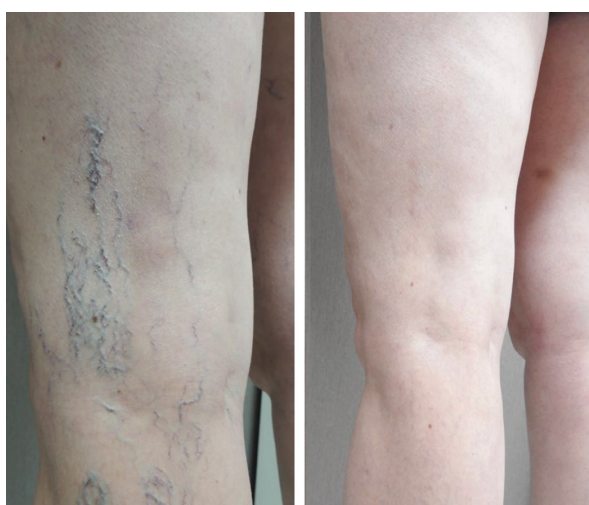3-10/VL 6 mm

FLUENCE/ENERGY


70 J/cm²

PULSE TIME

20 ms



Before and after / two treatment sessions with ZYE YAG® 1064 nm



Case Report:

ZYE YAG® 1064 nm in the Treatment of Vascular Lesions in the Lower Extremities

Carlos Eduardo de Freitas Jorge, vascular surgeon
Belo Horizonte - MG, Brazil

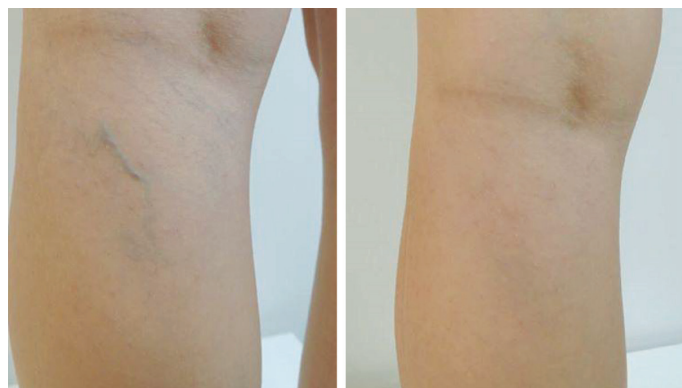This is a case report provided by the vascular surgeon Dr. Carlos Eduardo de Freitas Jorge, from Belo Horizonte, MG, Brazil, using the **ZYE YAG®** platform at 1064 nm with the **3-10/VL** handpiece.

- ▶ The **LongPulse®** fractional, non-ablative LASER generates the stimulation of subdermal collagen without the inconvenience of the posttreatment effects of fractional, non-ablative LASERs. Through the fractional LASER principle, which seeks to maintain the good condition of the tissue in the treated areas, the idea is to promote faster recovery, as well as reducing not only relative downtime, but also the relative risk of adverse effects, such as post inflammatory hyperpigmentation. Fractional, non-ablative LASER generates good results in the treatment of fine to moderate wrinkles, as well as other signs of sunlight-related aging.
- ▶ Other treatment recommendations commonly reported in bibliographic sources are atrophic scars, acne scars, surgical scars, stretch marks and even melasma and pigmentary lesions.
- ▶ **ZYE YAG®** LASER technology at 1064 nm, together with the **3-10/VL** handpiece, with sapphire window cooling (**COOL-&-CLEAR®** system), allows transdermic treatment of veins on the face and extremities, with the specificity necessary to ensure safe results.


HANDPIECE/SPOT
3-10/VL 6 mm

FLUENCE/ENERGY
70 J/cm²

PULSE TIME
20 ms



Before and after / one treatment session with ZYE YAG® 1064 nm



Case Report:

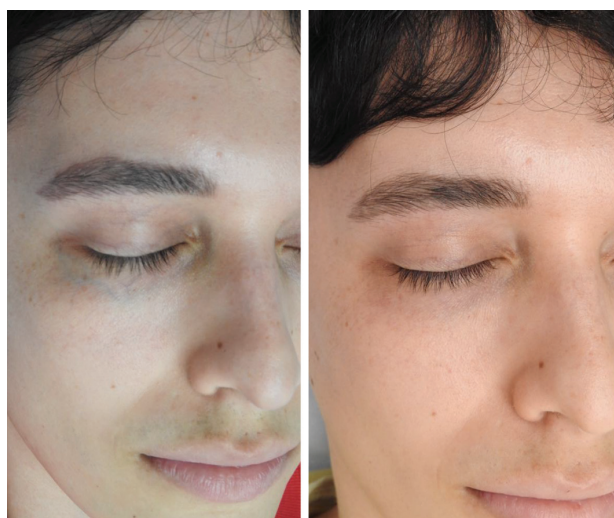ZYE YAG® 1064 nm in the Treatment of
Vascular Lesions on the Face

Carlos Eduardo de Freitas Jorge, vascular surgeon
Belo Horizonte - MG, Brazil

This is a case report provided by the vascular surgeon Dr. Carlos Eduardo de Freitas Jorge, from Belo Horizonte, MG, Brazil, using the **ZYE YAG®** platform at 1064 nm with the **3-10/VL** handpiece.

- ▶ The treatment of vascular lesions on the face is generally more complicated and must be more carefully evaluated than that of vascular lesions on the extremities. On the face, for example, the use of sclerotherapy can cause a reflux of the sclerotherapy agents into the arterioles, potentially resulting in serious complications, such as necrosis in certain areas. Greater benefits such as electrocoagulation are described in the literature, but even with this technology, adverse side effects can appear on the skin because of the low level of selectivity for blood vessels.
- ▶ The use of LASER 1064 nm has been broadly indicated for photothermolysis, or in other words, the selective absorption of light by hemoglobin and relatively low absorption by melanin, thereby ensuring protection for the surrounding skin and tissue.
- ▶ **ZYE YAG®** LASER technology at 1064 nm, together with the **3-10/VL** handpiece, with sapphire window cooling (**COOL-&-CLEAR®** system), allows transdermic treatment of veins on the face and extremities, with the specificity necessary to ensure safe results.

HANDPIECE/SPOT 3-10/VL 5 mm	HANDPIECE/SPOT 3-10/VL 6 mm
FLUENCE/ENERGY 80 J/cm ²	FLUENCE/ENERGY 60 J/cm ²
PULSE TIME 20 ms	PULSE TIME 20 ms
TWO SESSIONS	



Before and after / two treatment sessions with ZYE YAG® 1064 nm

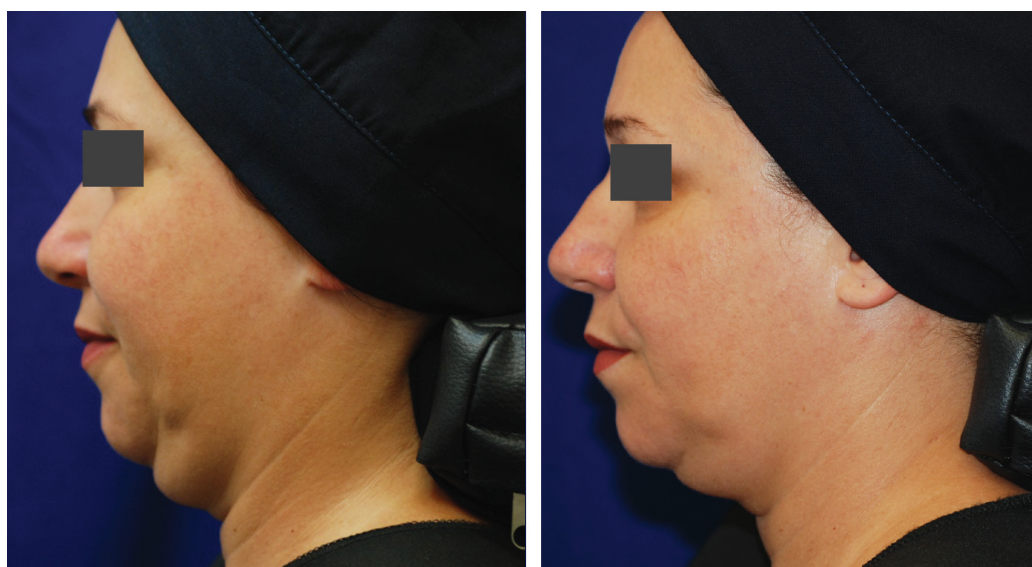


Case Report: LASER Tightening

Valéria Campos, dermatologist
Jundiaí - SP, Brazil

This is a case report provided by the dermatologist Dr. Valéria Campos, from Jundiaí, SP, Brazil. The case described aims at rejuvenation with the stimulation of deep collagen (skin tightening effect), using the **ZYE YAG®** platform at 1064 nm with the **5-15/LT** handpiece.

- ▶ Rejuvenation of the skin is a treatment that seeks to stimulate collagen, remove pigimentary lesions and even superficial vascular lesions. The idea is to attenuate lines and wrinkles, fight mild flaccidity, restore uniform coloration to the skin (removing undesired spots), as well as providing a toning effect and glow. The most modern technologies currently available include ablative fractional LASERs (for example: **DualMode®**), non-ablative fractional LASERs (for example: **ProDeep®**), nano (**ACROMA-QS®**) and picosecond LASERs, as well as those with long and quasi-continuous pulses (**ZYE YAG® INTENSE®**).



Before and after (six sessions)

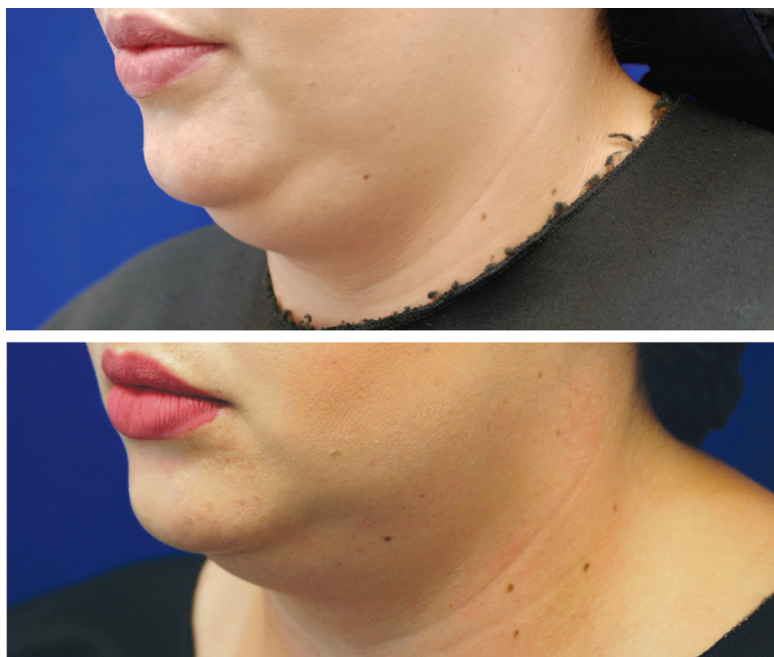

Case Report: LASER Tightening

Valéria Campos, dermatologist
Jundiaí - SP, Brazil

This is a case report provided by the dermatologist Dr. Valéria Campos, from Jundiaí, SP, Brazil. The case described aims at rejuvenation with the stimulation of deep collagen (skin tightening effect), using the **ZYE YAG®** platform at 1064 nm with the **5-15/LT** handpiece.

- ▶ Rejuvenation of the skin is a treatment that seeks to stimulate collagen, remove pigmentary lesions and even superficial vascular lesions. The idea is to attenuate lines and wrinkles, fight mild flaccidity, restore uniform coloration to the skin (removing undesired spots), as well as providing a toning effect and glow. The most modern technologies currently available include ablative fractional LASERs (for example: **DualMode®**), non-ablative fractional LASERs (for example: **ProDeep®**), nano (**ACROMA-QS®**) and picosecond LASERs, as well as those with long and quasi-continuous pulses (**ZYE YAG® INTENSE®**).

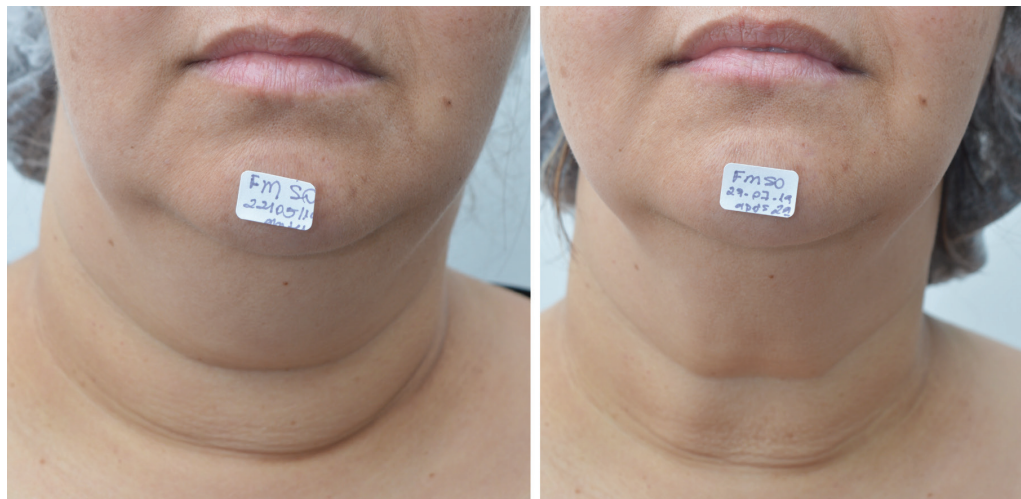

Before and after (seven sessions)

**Case Report:**
LASER Tightening**Valéria Campos**, dermatologist
Jundiaí - SP, Brazil

This is a case report provided by the dermatologist Dr. Valéria Campos, from Jundiaí, SP, Brazil. The case described aims at rejuvenation with the stimulation of deep collagen (skin tightening effect), using the **ZYE YAG®** platform at 1064 nm with the **5-15/LT** handpiece.

- ▶ Rejuvenation of the skin is a treatment that seeks to stimulate collagen, remove pigmentary lesions and even superficial vascular lesions. The idea is to attenuate lines and wrinkles, fight mild flaccidity, restore uniform coloration to the skin (removing undesired spots), as well as providing a toning effect and glow. The most modern technologies currently available include ablative fractional LASERS (for example: **DualMode®**), non-ablative fractional LASERS (for example: **ProDeep®**), nano (**ACROMA-QS®**) and picosecond LASERS, as well as those with long and quasi-continuous pulses (**ZYE YAG® INTENSE®**).



Before and after (two sessions)



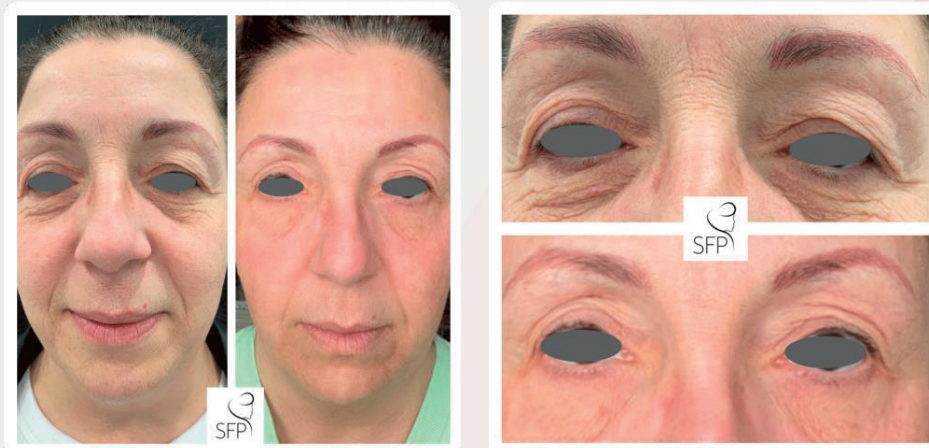Case report:

DualMode® Er:YAG for Full Face Resurfacing and Eyelid Flaccidity

Dr. Phillip Solomon, OTO/HNS Practicing Facial Plastic Surgery
Toronto, Ontario - Canada

This is a treatment report carried out by the plastic surgeon, Dr. Phillip Solomon, from Toronto, Ontario, Canada. Dr. Solomon used the DualMode® ZYE YAG® technologies. The patient received 2 treatments to her face and eyelid area.

- ▶ The patient presented with solar lentigines, mild to moderate wrinkles, rhytides and eyelid flaccidity
- ▶ As the aging process progresses, the appearance of wrinkles and flaccidity are common. The treatment of some wrinkles and flaccidity is more complicated, often due to their location. Treatments in the periorbital region must be precise and delicate because this area is very fine
- ▶ Various treatments are described for this region: lotions with retinoic acid, antioxidants and moisturizers, superficial and intermediate peeling and non-ablative and ablative fractional LASERS.
- ▶ The use of Er:YAG ablative fractional LASER promotes the vaporization of the damaged epidermis and partial dermal ablation. Dermal remodeling results in the replacement of damaged collagen and elastin by new collagen and elastin, improving the appearance of the crow's feet and flaccidity.
- ▶ The DualMode® handpiece, which is compatible with the ETHEREA-MX® and ZYE® platforms, has a wavelength of 2940 nm (Er:YAG), allowing more aggressive (in DualMode® – CO² like) and less aggressive treatments (single pulse) and even treatments with minimal ablative effect (Smooth pulse - InLift® and Truelift®). The choice of the ideal treatment mode improves the results, with the ability to change according to each patient's needs.



Before and after – 2 sessions

HANDPIECE	SPOT	PULSE TIME	FLUENCE
DualMode® Single Mode	8 mm – 100mtz	3 ms	12,5mj/mtz
DualMode® InLift®	InLift®	100 pulses per side	30mj/mtz
DualMode® Truelift®	Truelift®	50 pulses per side	15mj/mtz

HANDPIECE	SPOT	PULSE TIME	FLUENCE
DualMode® Single Mode	8 mm – 100mtz	2 ms	15 mj/mtz
DualMode® InLift®	InLift®	100 pulses per side	35 mj/mtz
DualMode® Truelift®	Truelift®	50 pulses per side	20 mj/mtz






etherea



 **vydence**
medical | From LASERS
to beauty within.

VYDENCE.COM

 @vydenceusa

**VYDENCE® Medical
Corporate Headquarters**

Rua Aldo Germano Klein, 359. CEAT
13573-470 São Carlos, SP. Brazil

**VYDENCE® Medical
Clinical Center**

Av. Fagundes Filho, 486 SL. 93
São Judas 04304-000 São Paulo - SP

**VYDENCE® Medical
USA Corporate Office**

601 Brickell Key Dr, STE 901
Miami, FL 33131 - USA